visited 7/20/2011

0008-3194/2003/21–27/$2.00/©JCCA 2003

Eagle's syndrome: a case of symptomatic calcification of the stylohyoid ligaments

Victor B Feldman, BSc, DC*

A case of symptomatic calcification of the stylohyoid ligaments is described. The patient presented with head and neck pain, with the neck pain being reproduced by palpation of the styloid process through the tonsillar fossa. Calcification or ossification of the stylohyoid ligament is a frequent, often incidental finding on radiographs, however when the source of pain is from the styloid process or calcified stylohyoid ligaments it is referred to as Eagle's syndrome. The symptoms may be confused with other causes of head and neck pain. This paper also discusses the pain patterns, clinical presentation, radiologic findings and treatment of Eagle's syndrome.
(JCCA 2003; 47(1):21–27)

KEY WORDS : Eagle's syndrome, stylohyoid ligament, styloid process, neck pain.

Un cas de calcification symptomatique des ligaments stylo-hyoïdiens est décrit. Le patient s'est présenté avec des maux de tête et une cervicalgie, la douleur au cou étant reproduite par palpation du processus styloïde par la fosse amygdalienne. La calcification ou l'ossification du ligament stylo-hyoïdien est fréquente et son apparition sur les radiographies est fortuite, mais lorsque la source de la douleur provient du processus styloïde ou de ligaments stylo-hyoïdiens calcifiés, on la désigne sous le nom de « syndrome d'Eagle ». Les symptômes peuvent être confondus avec d'autres causes de maux de tête et cervicalgie. Cet article discute également des schémas de la douleur, de la présentation clinique, des résultats radiologiques et du traitement du syndrome d'Eagle.
(JACC 2003; 47(1):21–27)

MOTS CLÉS : syndrome d'Eagle, ligament stylo-hyoïdien, processus styloïde, cervicalgie.

Case report

A 35-year-old male presented with a primary complaint of neck pain and stiffness of insidious onset for 2 months. The pain was more severe on the left and was exacerbated when he rotated his head either left or right. In addition, the patient reported a dull headache occurring two times per week. The headaches lasted for a few hours and began with the onset of the neck pain. The headaches were worse in the morning with the pain starting in the suboccipital region and travelling to become retro-orbital on the left. The symptoms were aggravated by renovation work at his home especially with overhead work. The previous medical history was unremarkable except for a tonsillectomy 10 years earlier.

Physical examination revealed a global decrease in active range of motion of the cervical spine with pain on the end-range range of extension and lateral flexion. Other provocative orthopedic tests included left extension-rotation (Kemp's test) and anterior nerve root testing (Doorbell test) at the C2–3 level on the left which produced local pain. Motion palpation revealed multiple joint restrictions with tenderness of the mid to upper cervical spine. Similar,

* Private Practice, Burnsville, Minnesota, USA.
Requests for reprints: Dr. Victor Feldman, 2424 117th Street, Burnsville, Minnesota, USA 55337. Fax: 952-890-5950.
© JCCA 2003.

visited 7/20/2011

but less intense findings were found on the right. The neurological examination was unremarkable.

Radiographic examination (Figure 1) demonstrated calcification of the stylohyoid ligaments with interruption of the calcification and pseudoarthrosis bilaterally. The disc spaces and posterior joints were normal. Subsequent to the radiographic findings re-examination of the patient revealed a hard bony mass, which was palpated in the left tonsillar fossa, increasing the patient's neck pain. A hard bony mass was also palpated in the right tonsillar fossa but did not produce any symptoms.

The patient was given a primary diagnosis of vertebrogenic headaches. In addition it was felt that the calcified stylohyoid ligaments were in some form contributing to the neck pain and a concomitant diagnosis of Eagle's syndrome was suggested. The patient underwent a short course of spinal manipulative therapy directed at the involved facet joints as well as manual soft-tissue therapy on the hypertonic cervical musculature and intra-oral tissues surrounding the stylohyoid ligaments. In addition the patient was instructed on a regimen of daily home upper cervical stretches. In approximately one month of treatment the patient reported remission of the headaches and a full and pain-free range of cervical motion.

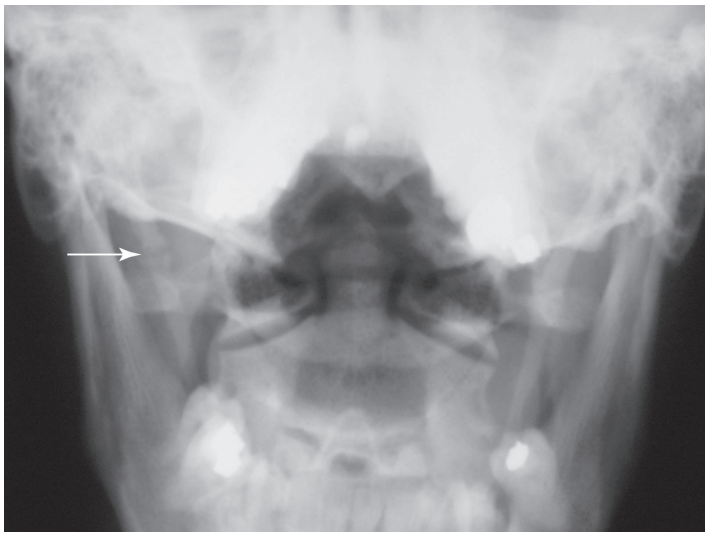

Figure 1A

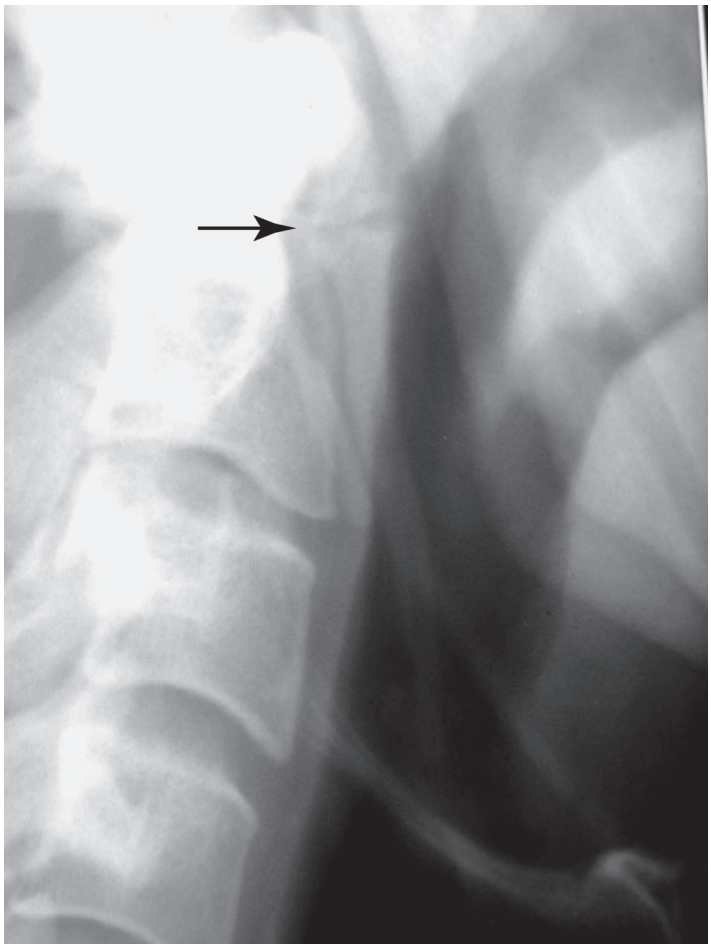

Figure 1B

APOM and Lateral films showing calcification of the stylohyoid ligaments with interruption of the calcification and pseudo-arthrosis bilaterally (arrow).

visited 7/20/2011

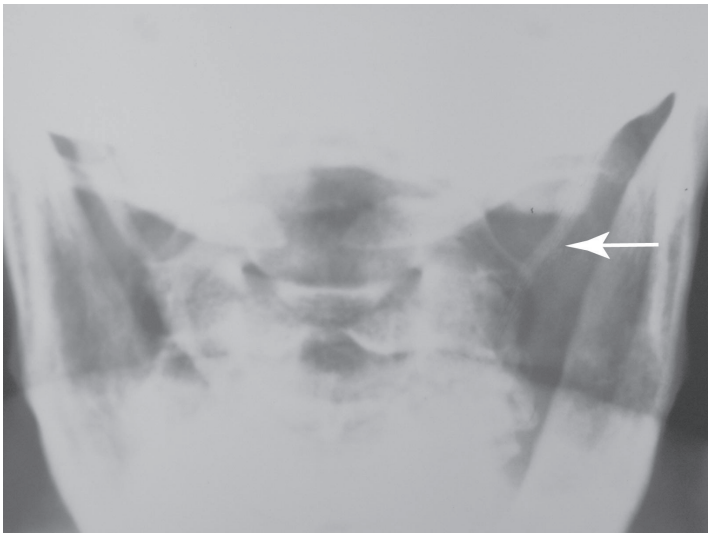

Figure 2A

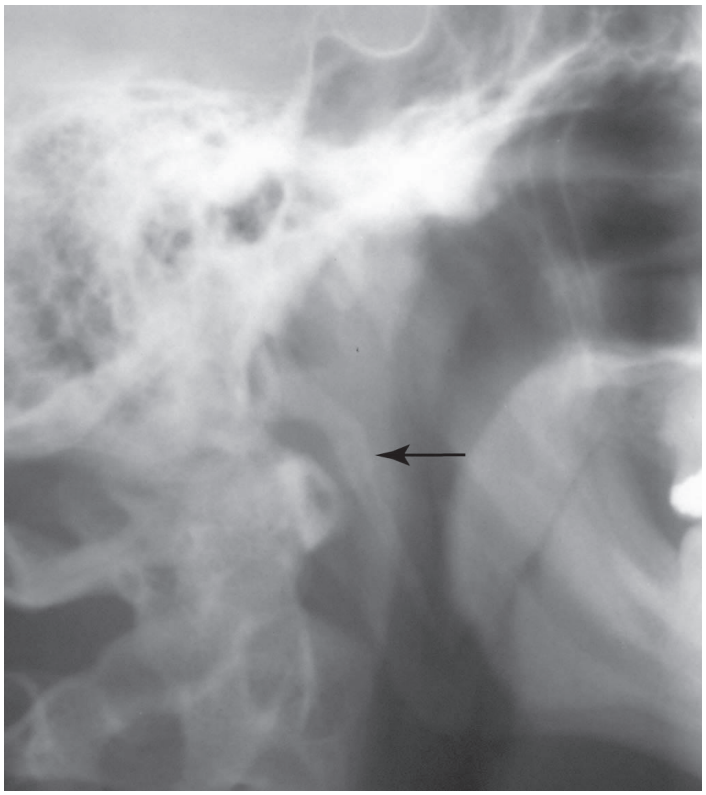

Figure 2B

APOM and Lateral films showing an elongated styloid process (Type I) (Courtesy Dr. Bill Hsu, Toronto, Ontario).

Discussion

Historical

Eagle's syndrome is defined as the symptomatic elongation of the styloid process or mineralization (ossification or calcification) of the stylohyoid ligament complex. This syndrome was first documented by Watt W. Eagle an otorhinolaryngologist.[1–5] Over a twenty-year period, Eagle reported over 200 cases and explained that the normal styloid process is approximately 2.5 to 3.0 centimeters in length. He observed that slight medial deviation of the styloid process, could result in severe symptoms of atypical facial pain.[6]

From Eagle's early descriptions, patients were categorized into two groups: those who had classical symptoms of a "foreign body" lodged in the throat with a palpable mass in the tonsillar region following tonsillectomy; and those with pain in the neck following the carotid artery distribution (carotid artery syndrome).[6,7] Although these two types have a common etiology, their symptomatology differ.

However, the mere presence of an elongated styloid process or mineralization of the stylohyoid complex radiographically in the presence of cervicopharyngeal pain does not automatically confirm a diagnosis of Eagle's syndrome. The reasons are three-fold. First, many patients with an ossified stylohyoid complex are asymptomatic. Second, there does not appear to be any correlation between the severity of pain and the extent of ossification of the stylohyoid complex.[8] Finally, the majority of symptomatic patients have had no recent history of tonsillectomy or any other cervicopharyngeal trauma.[8] Despite this, the literature still categorizes patients into those with a pain pattern following the carotid artery distribution and those with a classical palpable mass in the tonsillar region.

visited 7/20/2011

Epidemiology

In a review of 1771 panoramic radiographs, the incidence of mineralization of the stylohyoid complex was found to be 18.2%.[9] Despite these figures, only 1% to 5% of patients are symptomatic.[10]

Anatomy

The styloid process is a small, tapering projection of the temporal bone located anterior to the stylomastoid foramen. Eagle documented that the average length ranges from 2.5 to 3.0 centimeters.[5] Another study on 241 dissections revealed an average length of 3.17 centimeters with a range between 1.4 and 5.8 centimeters.[11] However, most authors agree that any measurement over 3 cm is enlarged. The styloid process lies between the internal and external carotid arteries, posterior to the tonsillar fossa and lateral to the pharyngeal wall.[12] The styloid process has attachments to three muscles and two ligaments. The stylohyoid ligament itself, extends from the tip of the styloid process to the lesser cornu of the hyoid bone. The stylomandibular ligament extends from the styloid process to the angle of the mandible. The three muscles include the stylopharyngeous, stylohyoid, and styloglossus. The nerve supply comes from the glossopharyngeal, facial, and hypoglossal nerves, respectively.

The internal jugular vein and the accessory, hypoglossal, vagus, and glossopharyngeal nerves are located medial to the styloid process. The glossopharyngeal nerve emerges from the anterior part of the jugular foramen, medial to the styloid process, where it then curves around the posterior border at the level of the origin of the stylohyoid muscle.[13] This anatomic relationship is important as a cause of glossopharyngeal neuralgia in reported cases with an elongated and or fractured styloid process as the etiologic cause.[14]

Clinical presentation

Clinically, the syndrome is most commonly seen after the age of 30 years.[12] There is no significant sex predilection in occurrence of mineralization of the styloid process, however, symptoms are more common in females.[15]

In Eagle's syndrome, the symptoms range from mild discomfort to acute neurologic and referred pain. These symptoms may include: Continuous pain in the throat even after tonsillectomy (40%), sensation of a foreign body in the pharynx (55%), difficulty swallowing, otalgia, headache, pain along the distribution of the external and internal carotid arteries, dysphagia (80%), pain on cervical rotation, facial pain, vertigo, and syncope.[10,12,15–17]

As mentioned previously, symptoms are divided into two groups. The first group of symptoms, are characterized by pain located in the areas where the fifth, seventh, eighth, ninth and tenth cranial nerves are distributed and occurs in most of the cases after tonsillectomy which may have been performed many years earlier.[18] Pain following tonsillectomy is presumably created by stretching or compressing the nerve or nerve endings of cranial nerves V,

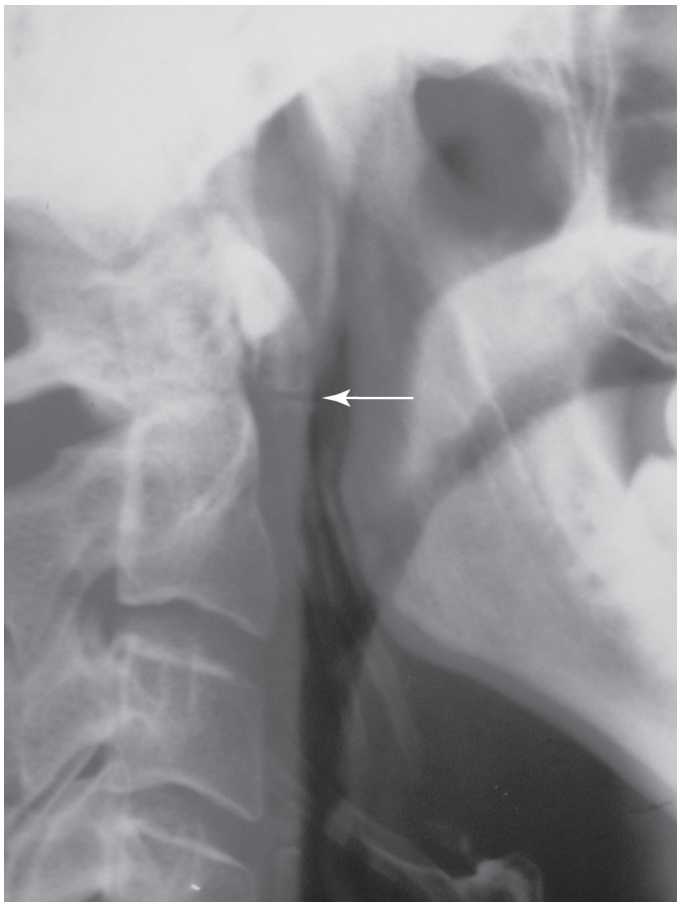

Figure 3

Lateral films showing a styloid process joined to a calcified stylohyoid ligament by a single pseudoarticulation (Type II). This gives the impression of an apparent articulation of an elongated styloid process (arrow).

visited 7/20/2011

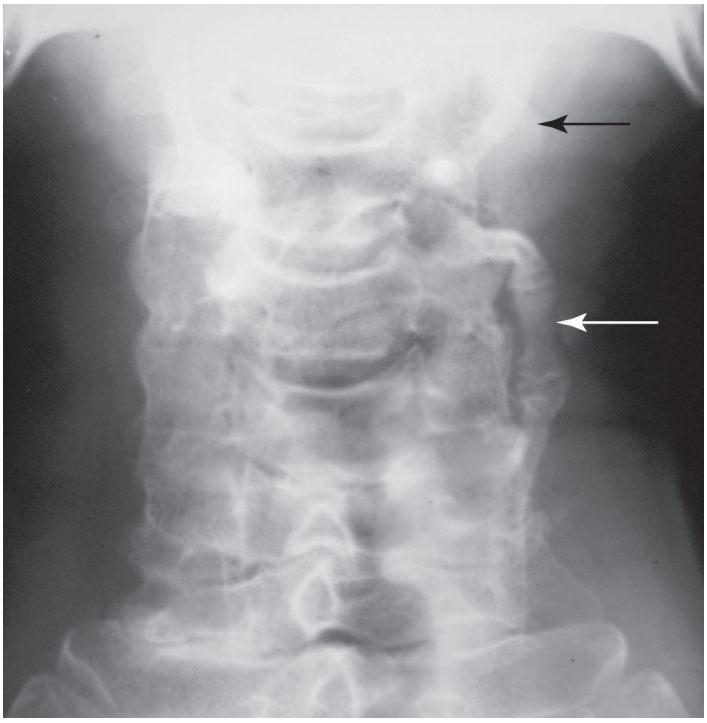

Figure 4A

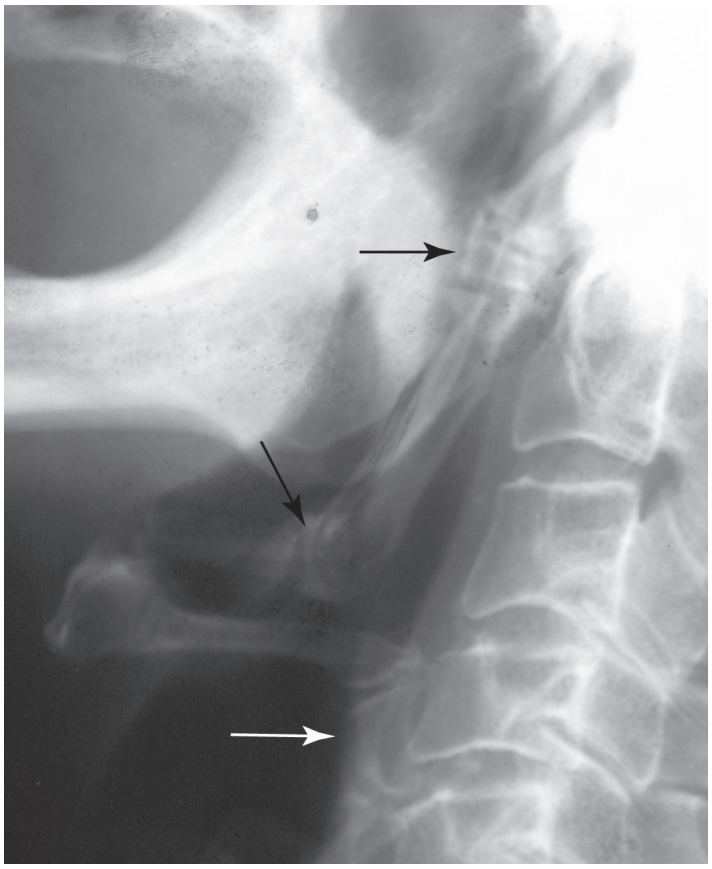

Figure 4B

AP and Lateral films showing a styloid process attached to multiple interrupted segments of an ossified stylohyoid (black arrow) and thyrohyoid (white arrow) ligaments (Type III). (Courtesy Dr. Rob Canterbury, Palmer College of Chiropractic, Davenport, Iowa).

VII, VIII, IX, or X in the tonsillar fossa either during healing (scar tissue) or shortly thereafter.[10]

Diagnosis and treatment

The diagnosis is based on the history of previous tonsillectomy or trauma to the cervical spine in conjunction with reproduction of symptoms during palpation of the tonsillar fossa. The elongated styloid process can be palpated by inserting a finger orally along the occlusal line posterior to the region of the tonsillar fossa. Pain is reproduced by palpation of the styloid process. Confirmation is made with radiographs showing an elongated styloid process or mineralization of the stylohyoid complex.[19]

The second type, the carotid artery syndrome, usually is not associated with tonsillectomy. The carotid artery syndrome is caused by mechanical irritation of the sympathetic nerve tissue in the walls of the internal and/or external carotid artery by the tip of the styloid process or the ossified ligament. This irritation produces referred pain in the respective area of vascularization.[15] Hence, if the external carotid artery is affected, the patient may complain of pain in the neck on turning the head, or pain radiation to the eye, ear, angle of the mandible, soft palate and nose. When the internal carotid artery is involved, pain over the entire head and larynx may be involved.[9]

Treatment has traditionally been surgical excision of the styloid process and/or the mineralized ligaments. However, a more conservative approach has been to attempt to

visited 7/20/2011

decrease any muscle spasm and scar tissue around the styloid process and mineralized ligaments. However, failing this attempt, surgery remains a viable alternative.

Other treatments have concentrated on steroid injections into the affected tissues with varying results.[20,21]

Radiology

Mineralization of the stylohyoid ligament may occur in various sites along its course and may be visualized on radiographs.

Pseudoarticulations may form which are related to the embryological development of this ligament. One radiographic classification system includes three types of radiographic appearances.[10]

The Type I pattern represents an uninterrupted, elongated styloid process (Figure 2). Type II is characterized by the styloid process apparently being joined to the stylohyoid ligament by a single pseudoarticulation. This gives the appearance of an articulated elongated styloid process and is the type present in our patient (Figure 3). Type III consists of interrupted segments of the mineralized ligament, creating the appearance of multiple pseudoarticulations within the ligament (Figure 4). Although the finding of an elongated styloid process or calcified/ossified stylohyoid ligament complex is often an incidental finding if asymptomatic, it has been documented in patients with mucopolysaccharidoses and diffuse idiopathic skeletal hyperostosis (DISH) each having their own inherent clinical complications.[22]

Conclusion

In patients presenting with symptoms in the throat with associated headaches or facial pain, a thorough detailed case history and physical examination of the head and neck are mandatory. The differential diagnosis of neoplasm, unerupted molars, temporomandibular dysfunction, inner ear problems and neuralgias should be included with an elongated styloid process as sources of head and neck pain.

The diagnosis of Eagle's syndrome is made with a history and finding of an elongated styloid process in the tonsillar fossa, of which palpation reproduces the symptomatology.

Traditionally, treatment has been one of surgical excision of the styloid process. However, a more conservative approach may be undertaken to decrease any muscle spasm or decrease fibrosis around the styloid process. An awareness of pain syndromes related to the styloid process is important to all health practitioners involved in the diagnosis and treatment of neck and head pain.

References

1 Eagle WW. Elongated styloid processes: report of two cases. Arch Otolaryngol 1937; 25:584–587.
2 Eagle WW. Elongated styloid process: further observations and a new syndrome. Arch Otolaryngol 1948; 47:630–640.
3 Eagle WW. Symptomatic elongated styloid process: report of two cases of styloid process-carotid artery syndrome with operation. Arch Otolaryngol 1949; 49:490–503.
4 Eagle WW. Elongated styloid process:symptoms and treatment. Arch Otolaryngol 1958; 67:172–176.
5 Eagle WW. The symptoms, diagnosis and treatment of the elongated styloid process. Am Surg 1962; 28:1–5.
6 Breault MR. Eagle's Syndrome: Review of the literature and implications in craniomandibular disorders. J Craniomandibular Practice 1986; 4(4):323–337.
7 Lorman JG, Biggs JR. The Eagle Syndrome. AJR 1983; 140:881–882.
8 Camarda AJ, Deschamps C, Forest D. Stylohyoid chain ossification: a discussion of etiology. Oral Surg Oral Med Oral Pathol 1989; 67:508–514.
9 Correll RW, Jensen JL, et al. Mineralization of the stylohyoid-stylomandibular ligament complex. Oral surg Oral med Oral path 1979; 48:286–291.
10 Langlais RP, Miles DA, Van Dis ML. Elongated and mineralized stylohyoid ligament complex: A proposed classification and report of a case of Eagle's syndrome. Oral Surg. Oral Med. Oral Pathol 1986; 61:527–532.
11 Frommer J. Anatomic variations in the stylohyoid chain and their possible clinical significance. Oral Surg 1974; 38:659–667.
12 Gossman JR, Tarsitano JJ. The styloid-stylohyoid syndrome. J Oral Surg 1977; 35:555–560.
13 Moffat DA, Ramsden RT, Shaw HJ. The styloid syndrome: aetiological factors and surgical management. J Laryngol Otol 1977; 91:279–294.
14 Armo TA. Diagnosis and treatment of a styloid fracture. Oral Surg 1960; 13:1423–1424.
15 Keur JJ, Campbell JP, et al. The clinical significance of the elongated styloid process. Oral Surg Oral Med Oral Pathol 1986; 61:399–404.
16 Lavine MH, Stoopack JC, Jerrold TL. Calcification of the stylohyoid ligament. Oral Surg Oral Med Oral Path 1968; 25:55– 58.
17 Mueller N, Hamilton S, Reid GD. Case Report 248. Skeletal Radiology 1983; 10:273–275.

visited 7/20/2011

18 Dolan EA, Mullen JB, Papayoanou J. Styloid-Stylohyoid Syndrome in the Differential Diagnosis of Atypical Facial Pain. Surg Neurol 1984; 21:291–294.
19 Lindeman P. The elongated styloid process as a cause of throat discomfort: Four case reports. J Laryngol 1985; 99:505–508.
20 Evans JT, Clairmont AA. The nonsurgical treatment of Eagle's syndrome. Ear Nose Throat 1976; 55:94–95.
21 Steinman EP. Styloid syndrome in absence of an elongated process. Acta Otolaryngol 1968; 66:347–356.
22 Resnick D, Niwayama G. Diagnosis of Bone and Joint Disorders, 3rd Edition, Philadelphia 1995; vol 6(95):4577.

HELP SUPPORT CHIROPRACTIC RESEARCH

CANADIAN CHIROPRACTIC RESEARCH FOUNDATION

The C.C.R.F. is a registered Charitable foundation dedicated to quality Chiropractic research. We appreciate your continued support.

Please send your

Tax Deductible Donation

TODAY:

Donations
and/or
Requests for Grant Applications
may be forwarded to:

Canadian Chiropractic Research Foundation
1396 Eglinton Avenue West
Toronto, Ontario M6C 2E4

Dr. Rob Allaby
Treasurer
Canadian Chiropractic Research Foundation