Visited 03/08/2018

NIH Public Access
Author Manuscript
J Reprod Med. Author manuscript; available in PMC 2010 August 17.

Published in final edited form as:
J Reprod Med. 2009 May ; 54(5): 273–280.

Uterosacral Colpopexy at the Time of Vaginal Hysterectomy:

Comparison of Laparoscopic and Vaginal Approaches

Charles R. Rardin, M.D., **Elisabeth A. Erekson, M.D.**, **Vivian W. Sung, M.D., M.P.H.**, **Renee M. Ward, M.D.**, and **Deborah L. Myers, M.D.**
From the Division of Urogynecology and Reconstructive Pelvic Surgery, Department of Obstetrics and Gynecology, Warren Alpert Medical School, Brown University, Providence, Rhode Island.

Abstract

OBJECTIVE—To compare the risk of ureteral compromise and of recurrent vault prolapse following vaginal vs. laparoscopic uterosacral vault suspension at the time of vaginal hysterectomy.

STUDY DESIGN—In this retrospective, cohort study, uterosacral ligament suspension was performed using either a vaginal or laparoscopic approach. The primary outcome was intraoperative ureteral compromise; secondary outcomes were postoperative anatomic result and recurrent prolapse. The Canadian Task Force Classification was II-2.

RESULTS—One hundred eighteen patients were included: 96 patients in the vaginal group and 22 patients in the laparoscopic group. Ureteral compromise was identified intraoperatively in 4 (4.2%) cases in the vaginal group; no ureteral compromise was observed in the laparoscopic group ($p = 0.33$). Failure at the apex, defined as stage ≥ II for point C, was seen in 6.3% of patients in the vaginal group as compared with 0% in the laparoscopic group; this difference did not achieve statistical significance. Similarly, trends toward lower recurrent symptomatic vault prolapse (10% vs. 0%), any symptomatic prolapse recurrence (12.5% vs. 4.6%), and higher postoperative Pelvic Organ Prolapse Quantification point C were observed in the laparoscopic group ($p > 0.05$ for all).

CONCLUSION—Laparoscopic uterosacral vault suspension following vaginal hysterectomy is a safe alternative to the vaginal approach.

Keywords

colpopexy; hysterectomy; laparoscopic surgery

Although the traditional surgical approach to uterine prolapse often starts with vaginal hysterectomy, it is generally acknowledged that hysterectomy alone does not address the underlying defects of vaginal support. Although several techniques of vaginal vault suspension at the time of hysterectomy have been described, 1 of the more popular is uterosacral ligament vaginal vault suspension. By affixing the vaginal vault to the proximal uterosacral ligament, the procedure can produce the desired effect of restoration of the native apical support structures.[1] One concern, however, is the possibility of injury to other structures close to the uterosacral ligaments, notably the ureters and rectum. One series

© Journal of Reproductive Medicine®, Inc.

Address correspondence to: Charles R. Rardin, M.D., Division of Urogynecology and Reconstructive Pelvic Surgery, Warren Alpert Medical School, Brown University, 695 Eddy Street, Suite 12, Providence, RI 02903 (crardin@wihri.org).

Presented at the Global Congress of Minimally Invasive Gynecology, 36th Annual Meeting of the American Association of Gynecologic Laparoscopists, Washington, D.C., November 14–17, 2007.

Financial Disclosure: The authors have no connection to any companies or products mentioned in this article.

NIH-PA Author Manuscript
NIH-PA Author Manuscript
NIH-PA Author Manuscript

Visited 03/08/2018

NIH-PA Author Manuscript

NIH-PA Author Manuscript

NIH-PA Author Manuscript

demonstrated a ureteral compromise rate of 11% during vaginal uterosacral ligament suspension.[2]

The laparoscopic approach to vault suspension after vaginal hysterectomy may be well suited to address these limitations. The ureter and rectum are generally readily identifiable by direct visualization, and therefore the surgeon's ability to avoid injury to these structures may be enhanced. A relaxing incision in the peritoneum between the ureter and the uterosacral ligament may also allow improved tissue dissection and identification of the deeper aspects of the ligament, as well as further enhancing the safety of the ureter. Several authors have demonstrated the feasibility of this procedure,[3–7] and cadaver studies have demonstrated that sutures in the uterosacral ligament placed laparoscopically have similar or slightly greater pull-out strength than those placed vaginally[8]; this may reflect the improved visualization and dissection available to the laparoscopic surgeon, with subsequent improved tissue capture. In addition, the laparoscopic approach facilitates concomitant laparoscopic procedures, such as paravaginal defect repair for the correction of anterior compartment defects.

Materials and Methods

In order to test the primary hypothesis that the laparoscopic approach to colpopexy at the time of vaginal hysterectomy enhances safety of the ureter, this retrospective cohort study comparing the vaginal and laparoscopic approaches was undertaken at a tertiary urogynecology and reconstructive pelvic surgery service. Subjects were identified from current procedure terminology coding databases for vaginal hysterectomy between July 2003 and December 2006 (to allow at least 6 months of follow-up data); office and surgical charts were then reviewed, and patients who underwent concurrent uterosacral ligament colpopexy, by either the vaginal or laparoscopic approach, were included for analysis. Concurrent prolapse or continence procedures were performed as indicated. All patients were evaluated preoperatively with standardized pelvic examination according to the International Continence Society's Pelvic Organ Prolapse Quantification (POP-Q) evaluation[9] as well as multichannel urodynamic testing. Surgery was performed by 1 of 2 attending urogynecologists (C.R.R. and D.L.M.) with fellows and residents; route of vault suspension was selected by surgeon and patient preferences.

Vaginal colpopexy was carried out at the conclusion of the hysterectomy, with bowel packed and Breisky-Navratil retractors used to identify the proximal uterosacral ligaments visually and by palpation. Permanent and/or delayed absorbable sutures were then used to suspend the vaginal cuff to the ligaments in a manner similar to that described by Barber.[2]

The laparoscopic approach was carried out after the vaginal closure following hysterectomy and prior to any other prolapse repair. After securing pneumoperitoneum and laparoscopic visualization, a vaginal probe was used to elevate the vaginal vault, thereby allowing visualization of the uterosacral ligaments. Using sharp dissection with monopolar cautery, peritoneal incisions between the proximal uterosacral ligament and the ureter on each side were performed. The proximal ligament was then dissected from the pelvic sidewall (Figure 1). CV-O Gore-tex suture on a THX-26 needle (W.L. Gore & Associates, Inc., Flagstaff, Arizona) was then passed doubly through the proximal uterosacral ligament; traction on the suture after the first purchase improved tissue capture on the second (Figure 2). The peritoneum overlying the midportion of the ligament was reefed in each suture to decrease the potential for internal herniation. The suture was then used to secure the proximal uterosacral ligament to the ipsilateral vaginal cuff, both anterior and posterior to the transverse cuff closure. One or 2 such sutures were placed on each side, and extracorporeal knot-tying technique was used to suspend the vault (Figure 3). Concomitant repairs were

Visited 03/08/2018

NIH-PA Author Manuscript

NIH-PA Author Manuscript

NIH-PA Author Manuscript

then carried out, laparoscopically and/or vaginally, as indicated. Intraoperative cystoscopy with intravenous indigo carmine administration was performed universally in both groups.

Patients were asked to return for routine postoperative visits at 2 and 6 weeks and 6 and 12 months after surgery and yearly thereafter. Objective outcomes were determined by means of repeated measures of Pop-Q evaluation, which was routinely performed at each postoperative visit with the patient in a semirecumbent position. Objective failure was diagnosed with a postoperative POP-Q stage II or greater (−1 cm relative to the hymen) for any compartment. Office charts and hospital records were reviewed to collect demographic and medical history, urodynamic and cystoscopic data, surgical information and clinical outcomes after the study was approved by the Institutional Review Board of Women and Infants' Hospital.

Descriptive statistics, Student's *t* test, χ^2, paired *t* test and Fisher's exact tests were performed as appropriate. All analyses were 2 tailed with p values < 0.05 considered statistically significant. Power analysis was performed, using the assumption of 11% and 1% ureteral compromise rate in the vaginal and laparoscopic groups, respectively, with 0.05 alpha and 0.20 beta settings; the required sample sizes using these assumptions, with equal numbers in each group, was 107 patients in each group. All statistical analyses were performed using STATA 9.1 (StataCrop, College Station, Texas).

Results

One hundred eighteen patients were included in our study; 96 underwent vaginal uterosacral ligament suspension (VUSLS), and 22 patients underwent laparoscopic uterosacral ligament suspension (LUSLS) at the time of vaginal hysterectomy (Table I). Overall mean age was 57.3 (SE 12.1) years old, without significant differences between groups. Our population was predominantly white (96.5%) and postmenopausal (66.2%). Prior surgery for prolapse was reported in 9.4% of VUSLS (9 of 96) patients and 9.1% (2/22) of LUSLS patients. Mean preoperative POP-Q measurements were similar in the 2 groups (Table II).

Concurrent procedures for prolapse and stress urinary incontinence were performed as appropriate in 92% (92/96) and 95.5% (21/22) of the VUSLS and LUSLS cases, respectively (Table III). The surgical approach to correction of the anterior compartment defects was different between the 2 groups, with LUSLS patients more commonly undergoing laparoscopic paravaginal defect repair (p < 0.001). Concurrent incontinence procedures were performed in 54.4% (63/118) of patients overall, without significant differences between groups; patients also underwent rectocele repair at similar rates between the 2 groups (p = 0.48).

Ureteral compromise was identified during intraoperative cystoscopy in 4 (4.2%) cases in the vaginal group; no ureteral compromise was observed in the laparoscopic group (p = 0.33). Additionally, 1 patient in the VUSLS group had vault suspension sutures removed and replaced intraoperatively due to suture placement in the rectum, detected on digital rectal examination. No patients in the LUSLS group required suture revision (p = 0.27). In 1 patient undergoing VUSLS, ureteral compromise continued despite intraoperative ureteral stent placement and release of vault suspension sutures. Hydronephrosis was seen on computed tomography in the immediate postoperative period but had resolved 4 weeks following surgery. The etiology of the ureteral compromise was unclear in this patient; either surgical compromise or long-standing pelvic organ prolapse may have caused this transient condition. Mean estimated blood loss was greater for the VUSLS group (362 ± 21.3 mL vs. 222 ± 17.3 mL, p = 0.003).

Visited 03/08/2018

NIH-PA Author Manuscript

NIH-PA Author Manuscript

NIH-PA Author Manuscript

Overall, immediate postoperative complications were few (Table IV). One patient from each group required reoperation within the first 30 days postoperatively: 1 VUSLS patient required revision of tension-free vaginal tape, while 1 LUSLS patient underwent diagnostic laparoscopy for persistent constipation and painful defecation; vault suspension sutures were not considered causative. There was a nonsignificant trend toward higher urinary retention rates (defined as requirement of catheter bladder drainage for >48 hours after surgery) among patients in the VUSLS group (29.8% vs. 4.6%, $p = 0.07$). Fourteen (14.6%) VUSLS patients and 2 (9.1%) LUSLS patients experienced pelvic and/or leg pain that was considered to be neuropathic in origin and related to the procedure during the postoperative period. This pain resolved with conservative treatment in 12 of the 14 VUSLS patients (78.6%) and both LUSLS patients (100%). The 2 VUSLS patients who did not respond to conservative therapy were treated with amitriptyline and/or referred for neurologic evaluation. Granulation tissue requiring silver nitrate application beyond 90 days after surgery occurred in 15.8% of patients in the VUSLS group and none in the laparoscopic group ($p = 0.046$).

Mean follow-up time in the vaginal group was 8.8 (±0.7) months and 10.8 (±1.36) months in the laparoscopic group. Although statistical significance was not observed, trends toward lower apical failure rates (6.3% vs. 0%), recurrent symptomatic vault prolapse requiring an intervention (10% vs. 0%) and any symptomatic prolapse recurrence requiring an intervention (12.5% vs. 4.6%) were observed in the laparoscopic group ($p > 0.05$ for all). Three of the 6 patients (50%) in the vaginal group with apical failures had received permanent sutures for the vault suspension. Vaginal vault support (mean postoperative POP-Q point C) was statistically significantly higher in the laparoscopic group (−7.0 vs. −5.9 for LUSLS and VUSLS, respectively; $p = 0.04$); other mean postoperative POP-Q measurements were similar between groups (Table V).

Mean change in individual patients' preoperative and postoperative POP-Q values was calculated in both the VUSLS and LUSLS groups (paired *t* test) and found to be non-significant ($p > 0.05$ for all). Among patients with preoperative anterior defects (greater than or equal to stage II), recurrent anterior prolapse was detected in 28.7% and 9.5% of patients in VUSLS and LUSLS groups, respectively ($p = 0.07$). Recurrent anterior prolapse requiring repeat surgery was encountered in 5.5% vs. 0% of the VUSLS and LUSLS groups, respectively (Table VI).

Recurrence of posterior compartment prolapse (POP-Q stage II or greater) was observed in 6 of 48 (12.5%) patients in the VUSLS group and 1 of 10 (10%) patients in the LUSLS group; 5 patients (10.4%) in the VUSLS vs. 0 patients in the LUSLS group underwent additional surgery for correction of symptomatic posterior compartment prolapse ($p = 0.25$). Among patients without preoperative posterior defects, de novo posterior compartment defects (POP-Q Stage II or greater) were detected in 3/48 (6.25%) and 1/12 (8.5%) of VUSLS and LUSLS patients, respectively ($p = 0.98$); 1 patient in each group elected to undergo additional surgery for this condition ($p = 0.40$).

Discussion

There is consensus among most pelvic reconstructive surgeons that hysterectomy via any route is unlikely to satisfactorily address the defects in supportive tissue that result in pelvic organ prolapse. Techniques for vaginal vault suspension, either concomitant with or remote from hysterectomy, available to surgeons include abdominal and laparoscopic sacral colpopexy, vaginal sacrospinous ligament and ileococcygeus fixation, and uterosacral ligament suspension; in addition, a variety of vaginal mesh procedures have been introduced more recently. Proponents of the uterosacral ligament suspension point out its goal of

Visited 03/08/2018

NIH-PA Author Manuscript

NIH-PA Author Manuscript

NIH-PA Author Manuscript

anatomic restoration of native support structures and normal vaginal axis and symmetry while avoiding use of mesh or graft materials and their attendant risks of erosion or complications of healing. Several authors have described laparoscopic uterosacral vault suspension, with or remote from hysterectomy, and published case series have supported the feasibility, safety and efficacy of the laparoscopic approach. Lin et al[4] described their experience with 133 such procedures, with follow-up of 2–7.3 years, and reported and overall apical failure rate of 12.8%.

Anatomic success rates of uterosacral ligament vault suspensions are generally favorable; recurrence rates for apical prolapse following this procedure have been reported from < 1% to 5%, with follow-up up to 5 years.[1,2,10] The safety of the procedure has been brought into some question, with reported rates of ureteral compromise and/or injury of 1–11%.[1,2,10–13] Indeed, the procedure is often highlighted as an illustration of the value of routine intraoperative cystoscopy. Aronson advocates “deep” rather than “high” uterosacral ligament suture placement, illustrating that anatomic relations and pelvic rotation of the lithotomy position place the uterosacral ligaments in a posterior, rather than cephalad, location; with this in mind, they reported a ureteral compromise rate of 0.24%.[14] It bears noting, however, that anatomic failure rates are not reported in this study. Ureteral safety may be one of several advantages of the laparoscopic approach; in the current study, we observed a 4.2% ureteral compromise rate among patients undergoing vaginal colpopexy, while none were seen in the laparoscopic group. This is consistent with published series on laparoscopic uterosacral vault suspension procedures that demonstrate similarly low rates of ureteral compromise; Seman et al reported 1 among 73 patients with ureteral compromise, and Lin et al observed no cases of ureteral compromise among their 133 patients.[4,7]

An additional potential advantage of the laparoscopic approach is the ability to use permanent suture for vault suspension, as the sutures are placed and knots tied outside of the vaginal lumen; this may serve to enhance the durability of the repair. In this series, 15.8% of patients in the vaginal colpopexy group experienced granulation tissue at the vaginal vault 90 days or more from surgery, requiring silver nitrate cauterization; no granulation was observed in the laparoscopic group. The goal of restoration of the integrity of the fibromuscular tube at the apex by reattaching the anterior and posterior aspects of the pericervical ring is enhanced, as the cuff closure is readily identifiable when hysterectomy is performed concurrently; each suture anchors anterior and posterior fascia and uterosacral ligament together. Another reported complication of the vaginal uterosacral ligament suspension is sensory nerve injury, with patients complaining of sharp buttock pain and numbness radiating down the center of the posterior thigh to the popliteal fossa within the first 24 hours from surgery. Flynn et al. described this complication in 3.8% of patients undergoing transvaginal uterosacral ligament suspension.[15] Our definition of neuropathic pain was broader and more inclusive, and no patients required surgical release of sutures; there was no significant difference between groups.

There are several limitations of the current study. With the exception of estimated blood loss, of the incidence of postoperative granulation tissue and of the location of postoperative point C (all statistically significantly favoring the laparoscopic approach but the clinical relevance of which is uncertain), the study lacked the power to detect significant differences between the laparoscopic and vaginal routes. The power analysis called for sample sizes of 107 patients in each group; this was well beyond what was available at our institution at the time of data collection. Apparent trends occurred toward lower urinary retention ($p = 0.07$) and lower recurrent anterior compartment prolapse in the laparoscopic group ($p = 0.07$), although differences in anterior compartment repairs (midline colporrhaphy in the vaginal group, paravaginal defect repair in the laparoscopic group) may account for this. Patients were assigned to groups in nonrandom fashion, according to patient and surgeon preference;

Visited 03/08/2018

NIH-PA Author Manuscript

NIH-PA Author Manuscript

NIH-PA Author Manuscript

although no statistically significant differences in age, race, parity, comorbidity or body mass index were observed, nonrandom patient assignment may introduce bias. Additionally, standardized quality-of-life data were not collected or analyzed to assess the functional and subjective outcomes of surgery.

In conclusion, although superiority of the laparoscopic approach was not demonstrated, this study supports laparoscopic uterosacral ligament suspension at the time of vaginal hysterectomy as a safe and effective alternative for surgeons who may prefer this approach for pelvic reconstructive surgery.

Acknowledgments

Dr. Erekson was supported by grant T32 HD0406740-04, Women and Infants Hospital/Brown Epidemiology/Clinical Trials, Department of Health and Human Services.

Dr. Sung was supported by grant 5-K12-HD050108-02, WIH/Brown Women's Reproductive Health Research Career Development Award, National Institute of Child Health and Human Development.

References

1. Shull BL, Bachofen C, Coates KW, et al. A transvaginal approach to repair of apical and other associated sites of pelvic organ prolapse with uterosacral ligaments. Am J Obstet Gynecol 2000;183:1365–1373. [PubMed: 11120498]
2. Barber MD, Visco AG, Weidner AC, et al. Bilateral uterosacral ligament vaginal vault suspension with site-specific endopelvic fascia defect repair for treatment of pelvic organ prolapse. Am J Obstet Gynecol 2000;183:1402–1410. [PubMed: 11120503]
3. Ostrzenski A. Laparoscopic colposuspension for total vaginal prolapse. Int J Gynecol Obstet 1996;55:147–152.
4. Lin LL, Phelps JY, Liu CY. Laparoscopic vaginal vault suspension using uterosacral ligaments: A review of 133 cases. J Minim Invasive Gynecol 2005;12:216–220. [PubMed: 15922978]
5. Miklos JR, Kohli N, Lucente V, et al. Site-specific fascial defects in the diagnosis and surgical management of enterocele. Am J Obstet Gynecol 1998;179:1418–1423. [PubMed: 9855575]
6. Carter JE, Winter M, Mendehlsohn S, et al. Vagina vault suspension and enterocele repair by Richardson-Saye laparoscopic technique: Description of training technique and results. J Soc Laparoendos Surg 2001;5:29–36.
7. Seman EI, Cook JR, O'Shea RT. Two-year experience with laparoscopic pelvic floor repair. J Am Assoc Gynecol Laparosc 2003;10:38–45. [PubMed: 12554992]
8. Culligan PJ, Miklos JR, Murphy M, et al. The tensile strength of uterosacral ligament sutures: A comparison of vaginal and laparoscopic techniques. Obstet Gynecol 2003;101:500–503. [PubMed: 12636953]
9. Bump RC, Mattiasson A, Bo K, et al. The standardization of terminology of female pelvic organ prolapse and pelvic floor dysfunction. Am J Obstet Gynecol 1996;175:10–17. [PubMed: 8694033]
10. Silva WE, Pauls RN, Segal JL, et al. Uterosacral ligament vault suspension: Five year outcomes. Obstet Gynecol 2006;108:255–263. [PubMed: 16880293]
11. Pettit PD, Petrou SP. The value of cystoscopy in major vaginal surgery. Obstet Gynecol 1994;84:318–320. [PubMed: 8041555]
12. Harris RL, Cundiff GL, Theofrastus JP, et al. The value of intraoperative cystoscopy in urogynecologic and reconstructive pelvic surgery. Am J Obstet Gynecol 1997;177:1367–1371. [PubMed: 9423737]
13. Amundsen CL, Flynn BJ, Webster GD. Anatomical correction of vaginal vault prolapse by uterosacral ligament fixation in women who also require a pubovaginal sling. J Urol 2003;169:1770–1774. [PubMed: 12686830]
14. Aronson MP, Aronson PK, Howard AE, et al. Low risk of ureteral obstruction with "deep" (dorsal/posterior) uterosacral ligament suture placement for transvaginal apical suspension. Am J Obstet Gynecol 2005;192:1530–1536. [PubMed: 15902153]

Visited 03/08/2018

15. Flynn MK, Weidner AC, Amundsen C. Sensory nerve injury after uterosacral ligament suspension. Am J Obstet Gynecol 2006;195:1869–1872. [PubMed: 17014812]

NIH-PA Author Manuscript

NIH-PA Author Manuscript

NIH-PA Author Manuscript

Visited 03/08/2018

NIH-PA Author Manuscript

NIH-PA Author Manuscript

NIH-PA Author Manuscript

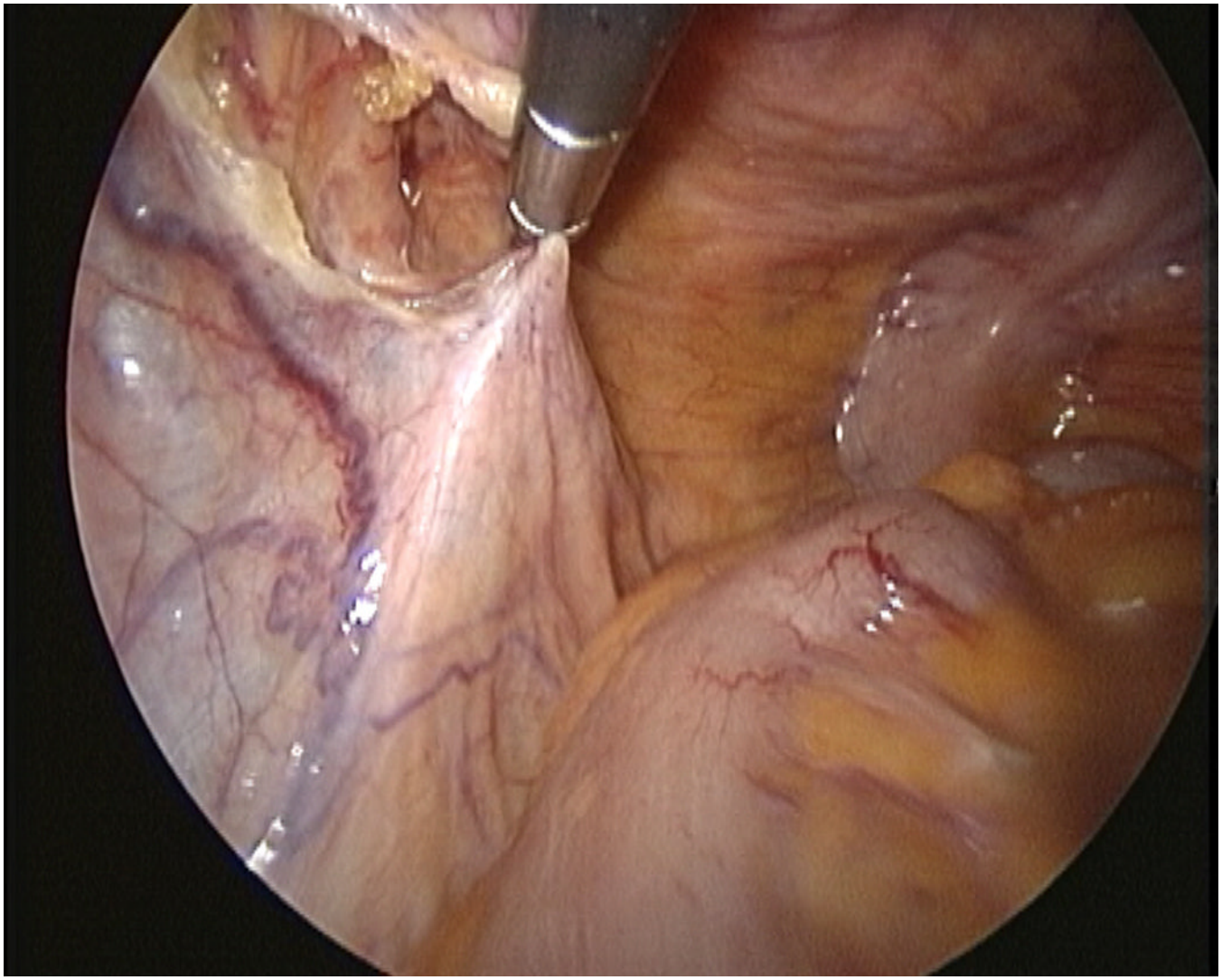

Figure 1.
Identification and dissection of left uterosacral ligament. (A) Peritoneal relaxing incision. (B) Left proximal uterosacral ligament. (C) Left ureter, Peritoneal incision and sidewall dissection may facilitate safe and complete uterosacral ligament identification and tissue capture.

Visited 03/08/2018

NIH-PA Author Manuscript

NIH-PA Author Manuscript

NIH-PA Author Manuscript

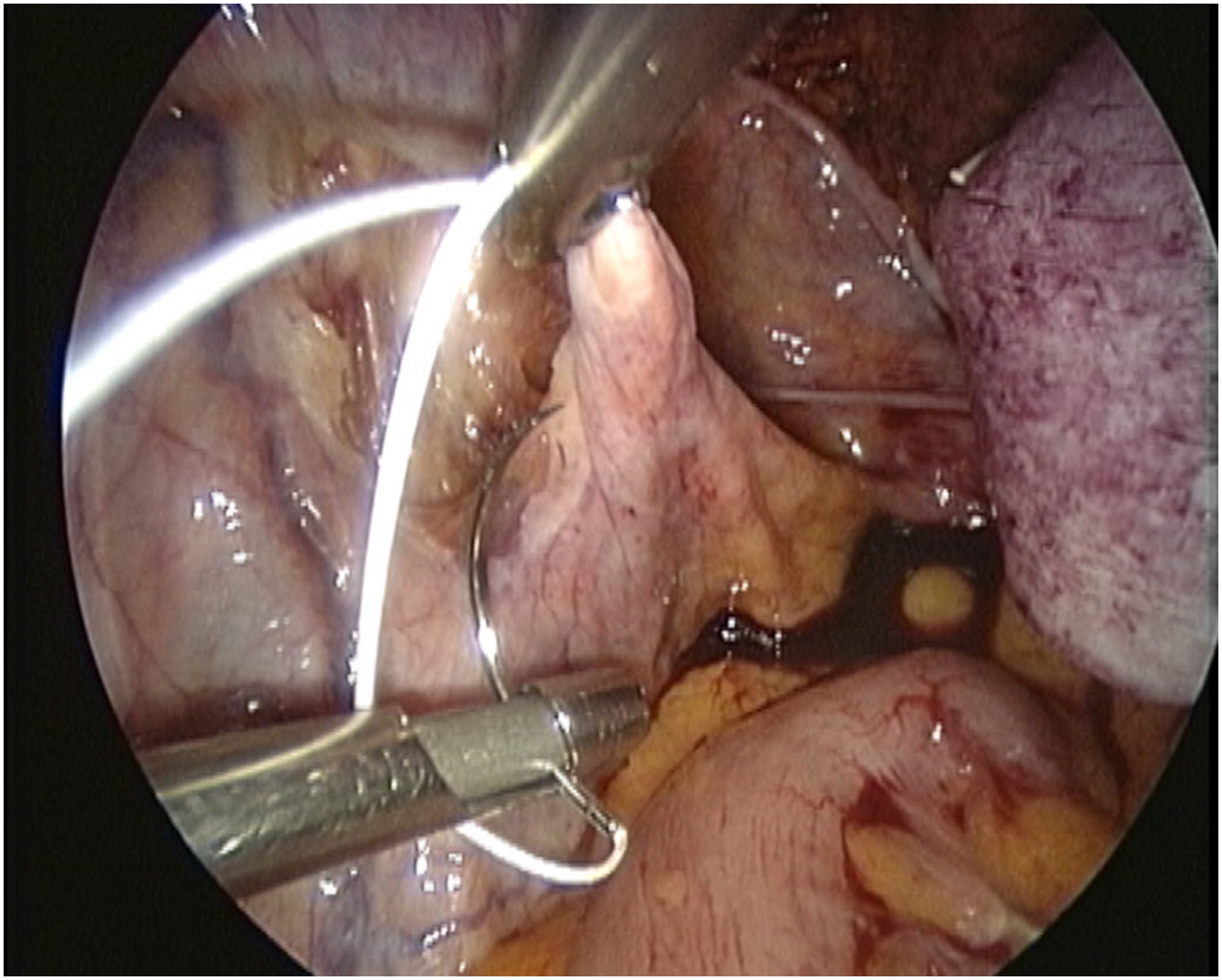

Figure 2.
Suture placement on left proximal uterosacral ligament. Each suture is passed doubly through the ligament; traction on the first purchase allows improved tissue capture on the second.

Visited 03/08/2018

NIH-PA Author Manuscript

NIH-PA Author Manuscript

NIH-PA Author Manuscript

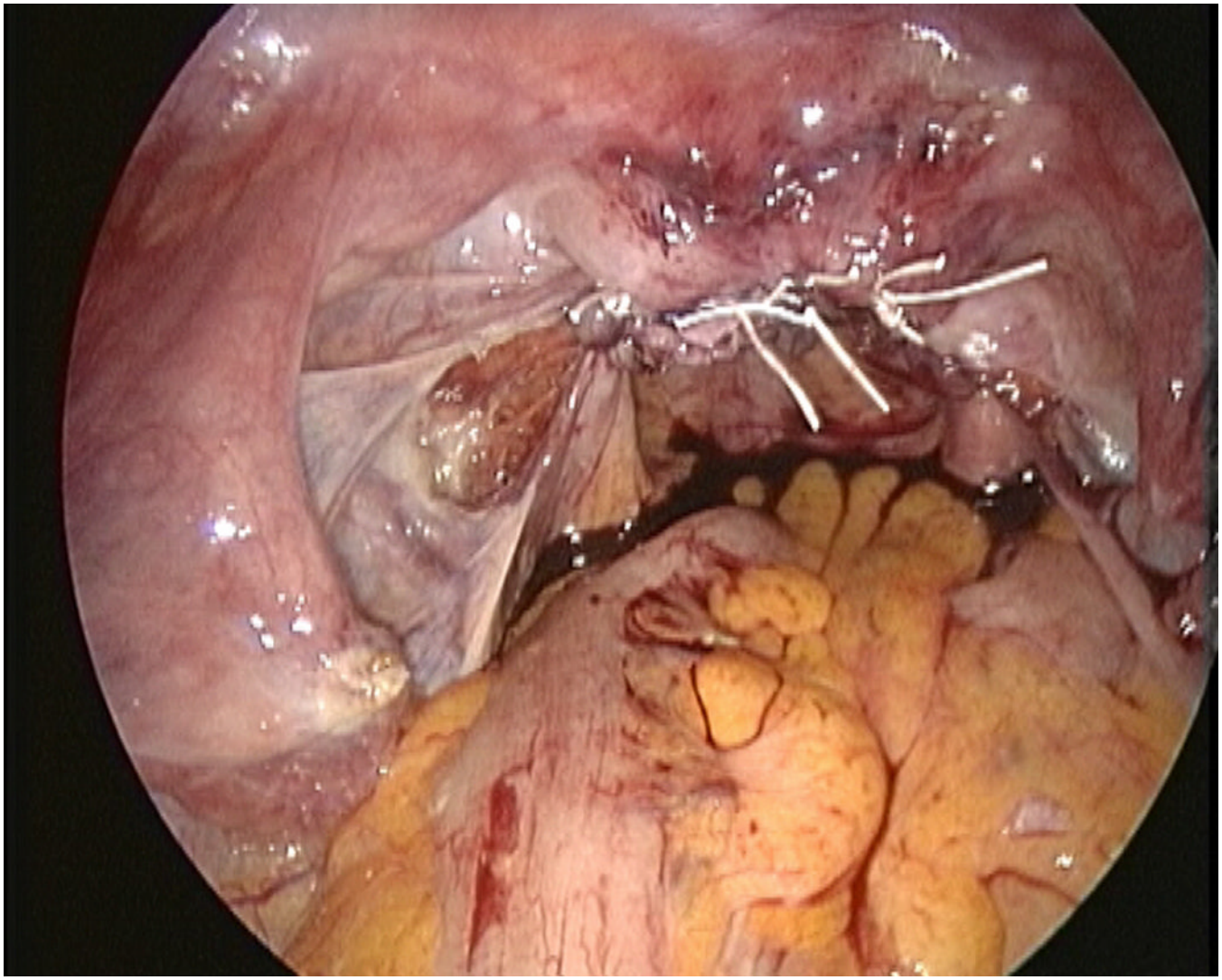

Figure 3.
Completion of colpopexy. (A) Left uterosacral ligament. (B) Right uterosacral ligament. (C) Vaginal vault. The vaginal vault is well supported, and the rectosigmoid is not compressed.

Visited 03/08/2018

NIH-PA Author Manuscript

NIH-PA Author Manuscript

NIH-PA Author Manuscript

Table I

Demographics and Preoperative Clinical Characteristics

Characteristic	Vaginal colpopexy (n = 96)	Laparoscopic colpopexy (n = 22)	p Value
Age (yr), mean (SE)	57.5 (12.9)	56.5 (8.3)	0.72
Parity, median (range)	2 (0–6)	3 (1–5)	0.39
Postmenopausal, n (%)	62 (64.6)	17 (77.3)	0.25
Race = white, n (%)	64 (95.5)	19 (100)	0.52
Prior incontinence procedures, n (%)			
RPU	5 (5.2)	1 (4.6)	0.89
Mersilene sling*	2 (2.1)	0	0.5
None	88 (91.7)	21 (95.5)	0.86
Prior prolapse surgeries, n (%)	9 (9.4)	2 (9.1)	0.97
Anterior colporrhaphy	6 (6.25)	2 (9.1)	0.64
Posterior colporrhaphy	5 (5.2)	2 (9.1)	0.49
Medical comorbidities, n (%)			
Hypertension	23 (24.0)	4 (19.1)	0.61
Diabetes mellitus	1 (1.0)	0	0.64
COPD/lung disease	7 (7.3)	1 (4.8)	0.68
Other	8 (8.3)	0	0.63
BMI, kg/m^2 (SE)	30.3 (1.9)	27.3 (1.2)	0.5

RPU = retropubic urethropexy, COPD = chronic obstructive pulmonary disease, BMI = body mass index.

*Mersilene sling by Ethicon, Inc., Somerville, New Jersey.

Visited 03/08/2018

NIH-PA Author Manuscript

NIH-PA Author Manuscript

NIH-PA Author Manuscript

Table II

Mean Preoperative POP-Q values

Value	Vaginal colpopexy (n = 96)	Laparoscopic colpopexy (n = 22)	p Value
Aa	0.7 (0.1)	−0.1 (0.2)	0.01
Ba	1.5 (0.2)	1.2 (0.3)	0.43
C	−0.3 (0.3)	−0.4 (0.4)	0.82
Ap	−1.2 (0.1)	−1.4 (0.2)	0.54
Bp	−0.9 (0.2)	−1.2 (0.2)	0.4
D	−4.9 (0.2)	−5.3 (0.3)	0.31

Values are given as mean (SE).

Visited 03/08/2018

NIH-PA Author Manuscript

NIH-PA Author Manuscript

NIH-PA Author Manuscript

Table III

Concurrent Surgical Procedures Performed at the Time of Vaginal Hysterectomy

Procedure	Vaginal colpopexy (n = 96)	Laparoscopic colpopexy (n = 22)	p Value
Anterior repair			
Colporrhaphy	73 (76)	0	<0.001
Colporrhaphy with mesh	2 (2.1)	0	0.49
LPVDR	2 (2.1)	20 (90.9)	<0.001
Incontinence procedures			
Burch	1 (1.0)	3 (13.6)	0.003
Sling	51 (53.1)	8 (36.0)	0.16
TVT	32 (34.4)	7 (35.0)	0.96
TOT	5 (5.2)	1 (4.5)	0.90
Mersilene	14 (15.1)	0	0.36
Posterior repair			
Colporrhaphy	51 (53.1)	11 (50.0)	0.48
Colporrhaphy with mesh	0	0	
Colporrhaphy with xenograft	5 (5.2)	0.28	
Oophorectomy	23 (24.0)	5 (22.7)	0.7

LPVDR = laparoscopic paravaginal defect repair, TVT = tension-free vaginal tape, TOT = transobturator tape.

Values are given as n (%).

Visited 03/08/2018

NIH-PA Author Manuscript

NIH-PA Author Manuscript

NIH-PA Author Manuscript

Table IV

Perioperative Data and Immediate Postoperative Period (First 90 Days After Surgery)

Data	Vaginal colpopexy (n = 96)	Laparoscopic colpopexy (n = 22)	p Value
Intraoperative cystoscopy	4 (4.2%)	0	0.33
Ureteral kink	1 (1.0%)	0	0.64
Ureteral stent	3 (3.1%)	0	0.41
Trocar injury	2 (2.1%)	0	0.50
Bladder laceration			
Intraoperative suture release[a]	5 (5.2%)	0	0.27
Immediate postoperative complications			
Blood transfusion	2 (2.1%)	0	0.50
Venous thromboembolic event	1 (1.0%)	0	0.75
Hematoma	1 (1.0%)	0	0.75
Infection	3 (3.1%)	0	0.41
Composite complications	5 (5.2%)	0	0.27
Postoperative complications			
Reoperation[b]	1 (1.0%)	1 (4.5%)	0.51
Ureteral compromise[c]	1 (1.0%)	0	0.75
Urinary retention[d]	20 (20.8%)	1 (4.6%)	0.07
Neuropathic pain[e]	14 (14.6%)	2 (9.1%)	0.49

Values are given as n (%).

[a]Uterosacral ligament suture release and replacement intraoperatively.

[b]Reoperation within the first 30 days after surgery.

[c]Ureteral compromise noted on radiologic imaging or cystoscopy postoperatively.

[d]Need for Foley catheter or clean, intermittent self-catheterization for >48 hours postoperatively.

[e]Pain or numbness radiating from the pelvis or buttock to the lower extremity, attributed to surgery.

Visited 03/08/2018

NIH-PA Author Manuscript

NIH-PA Author Manuscript

NIH-PA Author Manuscript

Table V

Mean Postperative POP-Q Values

Value	Vaginal colpopexy (n = 73)	Laparoscopic colpopexy (n = 21)	p Value
Aa	−1.8 (0.13)	−2.2 (0.16)	0.09
Ba	−1.7 (0.16)	−2.0 (0.29)	0.39
C	−5.9 (0.30)	−7.0 (0.25)	0.04
Ap	−2.3 (0.12)	−2.1 (0.18)	0.32
Bp	−2.2 (0.14)	−2.1 (0.19)	0.67

Values are given as mean (SE).

Visited 03/08/2018

NIH-PA Author Manuscript

NIH-PA Author Manuscript

NIH-PA Author Manuscript

Table VI

Postoperative Follow-up

Follow-up	Vaginal colpopexy (n = 96)	Laparoscopic colpopexy (n = 22)	p Value
Mean time	8.8 (0.7)	10.8 (1.36)	0.2
Granulation tissue*	15 (15.8%)	0	0.046
Any symptomatic prolapse	12(12.5%)	1 (4.5%)	0.29
Recurrent vault prolapse, ≥ stage II (total)	6 (6.3%)	0	0.22
Asymptomatic (observation)	1 (1.1%)	0	0.64
Pessary	1 (1.1%)	0	0.64
Surgery	4 (4.2%)	0	0.33
Preoperative anterior prolapse (≥ stage II)	93	21	
Recurrent anterior prolapse (total)	21/93 (28.7%)	2/21 (9.5%)	0.07
Asymptomatic	13 (20%)	2 (9.5%)	0.39
Pessary	4 (5.5%)	0	0.28
Surgery	4 (5.5%)	0 (0)	0.28

Values are given as mean (SE).

*Granulation tissue treated with silver nitrate cautery in the office >90 days postoperatively.