



6,919,915,968 visitors served.

TheFreeDictionary Google Bing

Word / Article Starts with Ends with Text



TEXT [social icons]

E-mail Password Remember Me Register Forgot password?



- Dictionary/thesaurus Medical dictionary Legal dictionary Financial dictionary Acronyms Idioms Encyclopedia Wikipedia encyclopedia

avascular necrosis Also found in: Dictionary/thesaurus, Legal, Acronyms, Encyclopedia, Wikipedia

0.01 sec.

On this page Word Browser

Like 0 Share: [social icons] Cite / link: [G+]

RECEIVED By Chris Tighe at 4:03 pm, Sep 25, 2014

avascular necrosis.

See coagulation necrosis.

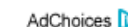Mosby's Medical Dictionary, 8th edition. © 2009, Elsevier.

Page tools Printer friendly Feedback Cite / link Add definition

This site:

Like 334k

Follow: [social icons] Share: [social icons]



necrosis (nekrō'sis),

- n 1. the death of a cell or group of cells in contact with living tissue. n 2. the local death of cells resulting from, e.g., loss of blood supply, bacterial toxins, or physical or chemical agents.

necrosis, avascular

n the consequence of temporary or permanent cessation of blood flow to the bones. The absence of blood causes the bone tissue to die, resulting in fracture or collapse of the entire bone.

necrosis, caseous

n a change commonly associated with tuberculosis and characterized by dry, soft, and cheesy tissue.

necrosis, exanthematous

n an acute necrotizing process involving the gingivae, jawbones, and contiguous soft tissues. It is of unknown cause, primarily affects children, and resembles noma. It differs from noma, however, in that it has a slight odor, tendency for self-limitation, low mortality rate, and normal leukocyte count. See also noma.

necrosis, gingival,

n death and degeneration of the cells and other structural elements of the gingivae (e.g., necrotizing ulcerative gingivitis).

necrosis, interdental,

n a progressive disease that destroys the tissue of the papillae and creates interdental craters. Advanced interdental necrosis leads to a loss of periodontal attachment.

necrosis, ischemic,

n death and disintegration of a tissue resulting from interference with its blood supply, thus depriving the tissues of access to substances necessary for metabolic sustenance. It may occur in the periodontal ligament as a result of occlusal trauma.

necrosis of epithelial attachment,

n the death of cells composing the epithelial attachment. In a specific periodontitis produced by organisms similar to Actinomyces, necrosis of the epithelial attachment may exist, permitting a rapid apical shift of the base of the pocket.

necrosis, periodontal ligament,

n necrosis of a portion of the periodontal ligament, usually resulting from traumatic injury (e.g., in occlusal traumatism). Much of this necrotic change is the result of ischemia.

Advertisement (Bad banner? Please let us know Remove Ads)

Related Ads Treatment Knee Hip Bursitis Hip Replacement Hip Joint Surgery Joint Pain Knee Hip Injury Osteoarthritis Ankle Arthritis Hip Pain Relief

My bookmarks Please log in or register to use bookmarks. You can also log in with Facebook, Google, Twitter, or Yahoo.

Advertisement (Bad banner? Please let us know Remove Ads)

necrosis, radiation,

n the death of tissue caused by radiation.

Mosby's Dental Dictionary, 2nd edition. © 2008 Elsevier, Inc. All rights reserved.

a-vas-cu-lar ne-cro-sis

necrosis resulting from deficient blood supply.

Farlex Partner Medical Dictionary © Farlex 2012

a-sep-tic ne-cro-sis (ā-sep'tik nĕ-krō'sis)

Death or decay of tissue due to local ischemia in the absence of infection.

Synonym(s): avascular necrosis.

Medical Dictionary for the Health Professions and Nursing © Farlex 2012

avascular necrosis; AVN focal death of tissue, due to loss of local blood supply, e.g. as in osteochondritis

Illustrated Dictionary of Podiatry and Foot Science by Jean Mooney © 2009 Elsevier Limited. All rights reserved.

Want to thank TFD for its existence? [Tell a friend about us](#), add a link to this page, or visit [the webmaster's page for free fun content](#).

Link to this page:

Please bookmark with social media, your votes are noticed and appreciated:



TAKE **FREE ONLINE COURSES**
FROM THE BEST UNIVERSITIES
IN THE WORLD.

[VIEW THE LATEST COURSES
AT EDX.ORG >>](#)


TAKE **FREE ONLINE COURSES**
FROM THE BEST UNIVERSITIES
IN THE WORLD.

[VIEW THE LATEST COURSES
AT EDX.ORG >>](#)

Advertisement (Bad banner? Please [let us know](#) [Remove Ads](#))

Advertisement (Bad banner? Please [let us know](#) [Remove Ads](#))

Charity ?



[Feed your brain, feed a hungry child](#)

Advertisement (Bad banner? Please [let us know](#) [Remove Ads](#))

Mentioned in

- [adhesive capsulitis](#)
- [aseptic necrosis](#)
- [avascular](#)
- [avascular necrosis of hip](#)
- [Bite Sign](#)
- [carpal bones](#)
- [coagulation necrosis](#)
- [factitious panniculitis](#)
- [frozen shoulder](#)
- [growing pains](#)
- [Legg-Perthes disease](#)
- [Observation Hip](#)
- [Osteochondroses](#)
- [postsurgery complications](#)
- [renal osteodystrophy](#)
- [scaphoid bone](#)
- [sickle cell disease](#)
- [silicone arthroplasty](#)
- [Thiemann syndrome](#)

References in periodicals archive

These are typically high-energy injuries in young patients and may result in significant morbidity and loss of future function resulting from **avascular necrosis** and secondary osteoarthritis (6,7).

Posterior hip dislocation and ipsilateral isolated femoral neck ... by *Henderson, L.; Johnston, A.; Mockford, B.; Craig, B.* / *Journal of Surgical Case Reports*

However, similar to Zyto's study, 6 four-part fractures uniformly had poor outcomes and poor Constant scores, mostly attributed to **avascular necrosis** of the humeral head and resulting arthrosis.

Three-and four-part proximal humerus fractures: evolution to ... by *Min, William; Davidovitch, Roy L.; Tejwani, Nirmal C.* / *Bulletin of the NYU Hospital for Joint Diseases*

Mark suffers from **avascular necrosis**, a condition that requires him to get a hip replacement.

DISABLED FATHER OF TWO SEEKS HELP PAYING RENT by *The Santa Fe New Mexican (Santa Fe, NM)*

[More results >>](#)


Medical browser

- [Avandia](#)
- [avantin](#)
- [Avapro](#)
- [avascular](#)
- [avascular graft](#)
- ▶ **avascular necrosis**
- [avascular necrosis of hip](#)
- [avascularization](#)
- [AVASIS](#)
- [Avastin](#)
- [AVATAR](#)
- [AVB](#)
- [AVC](#)
- [AVD](#)
- [AVE](#)
- [Avelina-black Iberian cattle](#)
- [Avellana compact distri...](#)

Full browser

- [avascular graft](#)
- [avascular graft](#)
- ▶ **avascular necrosis**
- [avascular necrosis of bone](#)
- [Avascular Necrosis of Femoral Head](#)
- [avascular necrosis of hip](#)
- [avascular necrosis of the femoral head](#)
- [avascular necrosis of the femoral head](#)
- [avascular necrosis of the femoral head](#)
- [avascular zone](#)
- [avascular zone](#)
- [avascular zone](#)
- [avascular zone](#)
- [avascularity](#)

TheFreeDictionary **Google**

 ?

Word / Article Starts with Ends with Text

Free Tools: For surfers: [Free toolbar & extensions](#) | [Word of the Day](#) | [Help](#)
 For webmasters: [Free content](#) | [Linking](#) | [Lookup box](#) | [Double-click lookup](#) 

[Mobile Site](#) | [Terms of Use](#) | [Privacy policy](#) | [Feedback](#) | [Advertise with Us](#) | Copyright © 2014 [Farlex, Inc.](#) a Mode Partner

Disclaimer
 All content on this website, including dictionary, thesaurus, literature, geography, and other reference data is for informational purposes only. This information should not be considered complete, up to date, and is not intended to be used in place of a visit, consultation, or advice of a legal, medical, or any other professional.