



REVIEWED

By Chris Tighe at 11:38 am, Aug 08, 2016

AAOS
AMERICAN ACADEMY OF
ORTHOPAEDIC SURGEONS

OrthoInfo

Your connection to expert orthopaedic information

Find an Orthopaedist

AAOS.org

- Home
- About Us
- Glossary
- Español & Portugués
- Videos & Multimedia
- Resources
- For Physicians

Parts of the Body

- Shoulder & Elbow
- Hand & Wrist
- Hip & Thigh
- Knee & Lower Leg
- Foot & Ankle
- Neck & Back

Health Centers

- Broken Bones & Injuries
- Diseases & Conditions
- Arthritis
- Tumors
- Sports Injuries & Prevention
- Children
- Bone Health
- Health & Safety

Treatment

- Treatments & Surgeries
- Joint Replacement
- Rehabilitation Exercise and Conditioning Handouts

Your Healthcare

- Patient Safety
- Patient Stories
- Resources

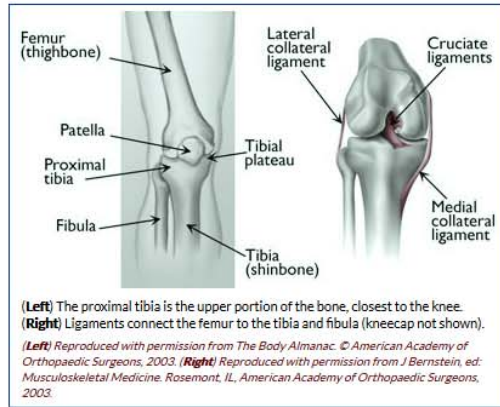
Fractures of the Proximal Tibia (Shinbone)

A fracture, or break, in the shinbone just below the knee is called a proximal tibia fracture. The proximal tibia is the upper portion of the bone where it widens to help form the knee joint.

In addition to the broken bone, soft tissues (skin, muscle, nerves, blood vessels, and ligaments) may be injured at the time of the fracture. Both the broken bone and any soft-tissue injuries must be treated together. In many cases, surgery is required to restore strength, motion, and stability to the leg, and reduce the risk for arthritis.

Anatomy

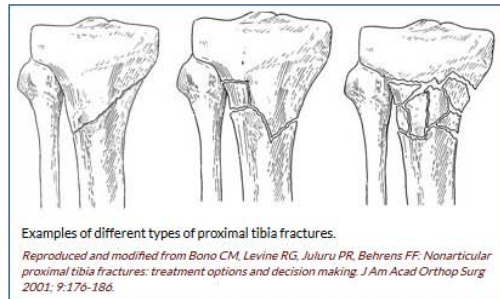
The knee is the largest weight-bearing joint of the body. Three bones meet to form the knee joint: the femur (thighbone), tibia (shinbone), and patella (kneecap). Ligaments and tendons act like strong ropes to hold the bones together. They also work as restraints — allowing some types of knee movements, and not others. In addition, the way the ends of the bones are shaped help to keep the knee properly aligned.



[Top of page](#)

Description

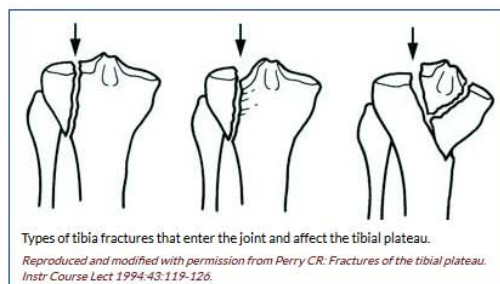
There are several types of proximal tibia fractures. The bone can break straight across (transverse fracture) or into many pieces (comminuted fracture).



Sometimes these fractures extend into the knee joint and separate the surface of the bone into a few (or many) parts. These types of fractures are called intra-articular or tibial plateau fractures.

The top surface of the tibia (the tibial plateau) is made of cancellous bone, which has a "honeycombed" appearance and is softer than the thicker bone lower in the tibia. Fractures that involve the tibial plateau occur when a force drives the lower end of the thighbone (femur) into the soft bone of the tibial plateau, similar to a die punch. The impact often causes the cancellous bone to compress and remain sunken, as if it were a piece of styrofoam that has been stepped on.

This damage to the surface of the bone may result in improper limb alignment, and over time may contribute to arthritis, instability, and loss of motion.



Proximal tibia fractures can be closed — meaning the skin is intact — or open. An open fracture is when a bone breaks in such a way that bone fragments stick out through the skin or a wound penetrates down

Like 21 Tweet

Print Article

Related Topics

- Fractures (Broken Bones)
- Open Fractures
- Helping Fractures Heal (Orthobiologics)
- Nonunions
- Arthritis of the Knee
- How to Use Crutches, Canes and Walkers
- Bone Health Basics
- Compartment Syndrome
- Infection After Fractures

Video: Fracture Healing



[View this video](#)

to the broken bone. Open fractures often involve much more damage to the surrounding muscles, tendons, and ligaments. They have a higher risk for problems like infection, and take a longer time to heal.

[Top of page](#)

Cause

A fracture of the upper tibia can occur from stress (minor breaks from unusual excessive activity) or from already compromised bone (as in cancer or infection). Most, however, are the result of trauma (injury).

Young people experience these fractures often as a result of a high-energy injury, such as a fall from considerable height, sports-related trauma, and motor vehicle accidents.

Older persons with poorer quality bone often require only low-energy injury (fall from a standing position) to create these fractures.

[Top of page](#)

Symptoms

- Pain that is worse when weight is placed on the affected leg
- Swelling around the knee and limited bending of the joint
- Deformity — The knee may look "out of place"
- Pale, cool foot — A pale appearance or cool feeling to the foot may suggest that the blood supply is in some way impaired.
- Numbness around the foot — Numbness, or "pins and needles," around the foot raises concern about nerve injury or excessive swelling within the leg.

If you have these symptoms after an injury, go to the nearest hospital emergency room for an evaluation.

[Top of page](#)

Doctor Examination

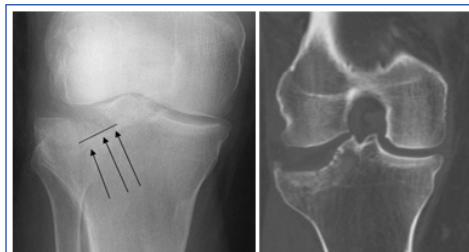
Medical History and Physical Examination

Your doctor will ask for details about how the injury happened. He or she will also talk to you about your symptoms and any other medical problems you may have, such as diabetes.

Your doctor will examine the soft tissue surrounding the knee joint. He or she will check for bruising, swelling, and open wounds, and will assess the nerve and blood supply to your injured leg and foot.

Tests

- **X-rays.** The most common way to evaluate a fracture is with x-rays, which provide clear images of bone. X-rays can show whether a bone is intact or broken. They can also show the type of fracture and where it is located within the tibia.
- **Computed tomography (CT) scan.** A CT scan shows more detail about your fracture. It can provide your doctor with valuable information about the severity of the fracture and help your doctor decide if and how to fix the break.



Doctors often use both x-rays (left) and CT scans (right) to determine the location and displacement of the fragments of broken bone.

- **Magnetic resonance imaging (MRI) scan.** An MRI scan provides clear images of soft tissues, such as tendons and ligaments. Although it is not a routine test for tibia fractures, your doctor may order an MRI scan to help determine whether there are additional injuries to the soft tissues surrounding your knee. In addition, if you have all the signs of a tibial plateau fracture, but x-rays are negative, your doctor may order an MRI scan. When bone is injured there is often reaction in the bone marrow which can be detected on MRI and means that a fracture has occurred.
- **Other tests.** Your doctor may order other tests that do not involve the broken leg to make sure no other body parts are injured (head, chest, belly, pelvis, spine, arms, and

[Top of page](#)

Treatment

A proximal tibia fracture can be treated nonsurgically or surgically. There are benefits and risks associated with both forms of treatment.

Whether to have surgery is a combined decision made by the patient, the family, and the doctor. The preferred treatment is accordingly based on the type of injury and the general needs of the patient.

When planning treatment, your doctor will consider several things, including your expectations, lifestyle, and medical condition.

In an active individual, restoring the joint through surgery is often appropriate because this will maximize the joint's stability and motion, and minimize the risk of arthritis.

In other individuals, however, surgery may be of limited benefit. Medical concerns or pre-existing limb problems might make it unlikely that the individual will benefit from surgery. In such cases, surgical treatment may only expose these individuals to its risks (anesthesia and infection, for example).

Emergency Care

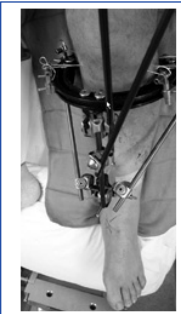Open fractures. If the skin is broken and there is an open wound, the underlying fracture may be exposed to bacteria that might cause infection. Early surgical treatment will cleanse the fracture surfaces and soft tissues to lessen the risk of infection.

External fixation. If the soft tissues (skin and muscle) around your fracture are badly damaged, or if it will take time before you can tolerate a longer surgery because of health reasons, your doctor may apply a temporary external fixator. In this type of operation, metal pins or screws are placed into the middle of the femur (thighbone) and tibia (shinbone). The pins and screws are attached to a bar outside the skin. This device holds the bones in the proper position until you are ready for surgery.

Compartment syndrome. In a small number of injuries, soft-tissue swelling in the calf may be so severe that it threatens blood supply to the muscles and nerves in the leg and foot. This is called compartment syndrome and may require emergency surgery. During the procedure, called a fasciotomy, vertical incisions are made to release the skin and muscle coverings. These incisions are often left open and then stitched closed days or weeks later as the soft tissues recover and swelling resolves. In some cases, a skin graft is required to help cover the incision and promote healing.

Nonsurgical Treatment

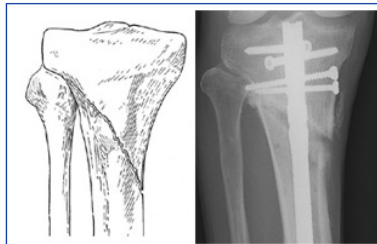
Nonsurgical treatment may include casting and bracing, in addition to restrictions on motion and weight bearing. Your doctor will most likely schedule additional x-rays during your recovery to monitor whether the bones are healing well while in the cast. Knee motion and weight-bearing activities begin as the injury and method of treatment allow.



Soon after an accident, the injured skin and soft tissues may be further harmed by surgery. In this event, a temporary external fixator may be applied to support the limb until the soft tissues recover and surgery can safely be performed.

Surgical Treatment

There are a few different methods that a surgeon may use to obtain alignment of the broken bone fragments and keep them in place while they heal.



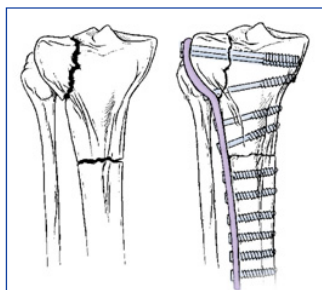
(Left) A proximal tibia fracture. (Right) The same type of fracture treated with intramedullary nailing (rod).

Reproduced with permission from Bono CM, Levine, RG, Rao JP, Behrens FF: Nonarticular Proximal Tibia Fractures: Treatment Options and Decision Making. J Am Acad Orthop Surg 2001; 9:176-186.

Internal fixation. During this type of procedure, the bone fragments are first repositioned (reduced) into their normal position. They are held together with special devices, such as an intramedullary rod or plates and screws.

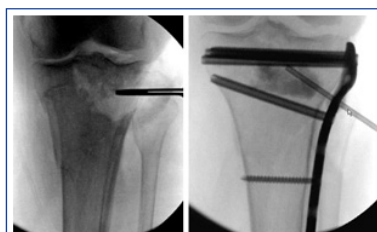
In cases in which the upper one fourth of the tibia is broken, but the joint is not injured, a rod or plate may be used to stabilize the fracture. A rod is placed in the hollow medullary cavity in the center of the bone. A plate is placed on the outside surface of the bone.

Plates and screws are commonly used for fractures that enter the joint. If the fracture enters the joint and pushes the bone down, lifting the bone fragments may be required to restore joint function. Lifting these fragments, however, creates a hole in the cancellous bone of the region. This hole must be filled with material to keep the bone from collapsing. This material can be a bone graft from the patient or from a bone bank. Synthetic or naturally occurring products which stimulate bone healing can also be used.



Fractures that extend into the knee joint frequently require plate fixation. The plate is applied to the surface of the bone.

Reproduced with permission from Koval KJ, Helfet DL: Tibial Plateau Fractures: Evaluation and Treatment. J Am Acad Orthop Surg 1995; 3: 86-94.



Fractures that are sunken (shown left) must be elevated back up to restore the joint. This reduces the risk of arthritis and instability. When the depressed joint pieces are lifted, a hole often remains below (shown right). This can be filled with various types of bone graft, synthetic or naturally occurring materials.

External fixators. In some cases, the condition of the soft tissue is so poor that the use of a plate or rod might threaten it further. An external fixator (described under Emergency Care above) may be considered as final treatment. The external fixator is removed when the injury has healed.

[Top of page](#)

Recovery

Pain Management

Pain after an injury or surgery is a natural part of the healing process. Your doctor and nurses will work to reduce your pain, which can help you recover faster.

Medications are often prescribed for short-term pain relief after surgery or an injury. Many types of medicines are available to help manage pain, including opioids, non-steroidal anti-inflammatory drugs (NSAIDs), and local anesthetics. Your doctor may use a combination of these medications to improve pain relief, as well as minimize the need for opioids.

Be aware that although opioids help relieve pain after surgery or an injury, they are a narcotic and can be addictive. Opioid dependency and overdose has become a critical public health issue in the U.S. It is important to use opioids only as directed by your doctor. As soon as your pain begins to improve, stop taking opioids. Talk to your doctor if your pain has not begun to improve within a few days of your treatment.

Early Motion

Your doctor will decide when it is best to begin moving your knee in order to prevent stiffness. This depends on how well the soft tissues (skin and muscle) are recovering and how secure the fracture is after having been fixed.

Early motion sometimes starts with passive exercise: a physical therapist will gently move your knee for you, or your knee may be placed in a continuous passive motion machine that cradles and moves your leg.

If your bone was fractured in many pieces or your bone is weak, it may take longer to heal, and it may be a longer time before your doctor recommends motion activities.

Weight Bearing

To avoid problems, it is very important to follow your doctor's instructions for putting weight on your injured leg.

Whether your fracture is treated with surgery or not, your doctor will most likely discourage full weight bearing until some healing has occurred. This may require as much as 3 months or more of healing before full weight bearing can be done safely. During this time, you will need crutches or a walker to move around. You may also wear a knee brace for additional support.

Your doctor will regularly schedule x-rays to see how well your fracture is healing. If treated with a brace or cast, these regular x-rays show your doctor if the bone is changing position. Once your doctor determines that your fracture is not at risk for changing position, you may start putting more weight on your leg. Even though you can put weight on your leg, you may still need crutches or a walker at times.

Rehabilitation

When you are allowed to put weight on your leg, it is very normal to feel weak, unsteady, and stiff. Even though this is expected, be sure to share your concerns with your doctor and physical therapist. A rehabilitation plan will be designed to help you regain as much function as possible.

Your physical therapist is like a coach guiding you through your rehabilitation. Your commitment to physical therapy and making healthy choices can make a big difference in how well you recover. For example, if you are a smoker, your doctor or therapist may recommend that you quit. Some doctors believe that smoking may prevent bone from healing. Your doctor or therapist may be able to recommend professional services to help you quit smoking.

[Top of page](#)

Outcome

Because proximal tibial fractures may involve a weight-bearing joint in an active individual, there are some long-term concerns. These include loss of knee motion and stability, as well as long-term arthritis.

Your doctor will discuss your own personal concerns, risks, and reasonable expectations. He or she will also discuss the impact these may have on activities of daily living, work, family responsibilities, and recreational activities.

What To Discuss With Your Orthopaedic Surgeon

1. What are my unique risks and benefits with nonsurgical and surgical treatment?
2. How might this injury affect my long-term expectations for daily living activities, work, and recreational activities?
3. Do I have a medical or social history (smoking, recreational drug, alcohol) that might have an impact on my treatment or outcome?
4. If I get arthritis, what can I expect and what are my options?
5. After treatment begins (surgical or nonsurgical) when can I expect to bear weight and bend my knee?
6. How will the recovery phase affect work and family responsibilities?
7. What kind of help, if any, will I need during my recovery?
8. If I have surgical treatment and a "bone filler" or substitute is used, what are my options? What are the risks and benefits?
9. Will I be on anticoagulation medications ("blood thinners")? If yes, which one and for how long?

[Top of page](#)

Last reviewed: July 2013

Contributed and/or Updated by: Stephen Kottmeier, MD

Peer-Reviewed by: Brett Crist, MD; Robert P. Dunbar, MD; Stuart J. Fischer, MD

[Contributor Disclosure Information](#)



Co-developed by the Orthopaedic Trauma Association

AAOS does not endorse any treatments, procedures, products, or physicians referenced herein. This information is provided as an educational service and is not intended to serve as medical advice. Anyone

Information provided on this website is for informational purposes only. If you are seeking specific orthopaedic advice or assistance, you should consult your orthopaedic surgeon, or locate one in your area through the AAOS "Find an Orthopaedist" program on this website.

[Editorial Board & Staff](#)

[Contributors](#)

[Online Agreements](#)

[Linking Policy](#)

[Advertising & Sponsorship](#)

[Privacy Policy](#)

[AAOS News Bureau](#)

Copyright © 1995-2016 by the American Academy of Orthopaedic Surgeons. All material on this website is protected by copyright. All rights reserved. This website also contains material copyrighted by third parties.