



Lumbar Radiculopathy

f SHARE

p PIN IT

SUBSCRIBE



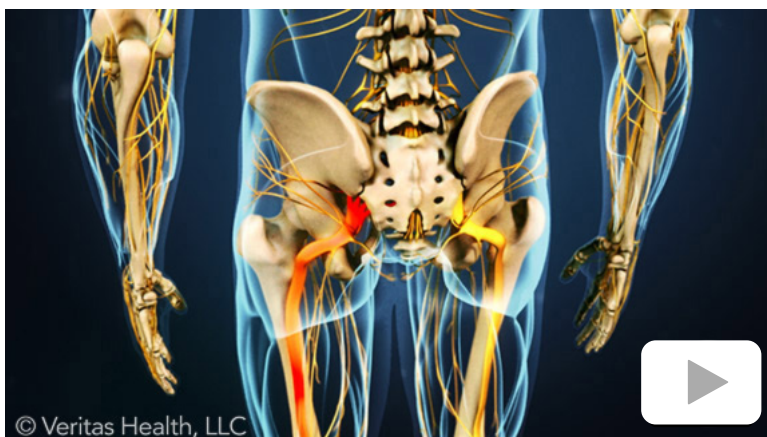By [Ari Ben-Yishay, MD](#)

Updated: 04/25/2012 | [Peer Reviewed](#)

Radicular pain is often referred to as radiculopathy, and in lay terms is often described as sciatica. This type of pain is often deep and steady, and can usually be reproduced with certain activities and positions, such as sitting or walking...

Radicular pain is often secondary to compression or inflammation of a spinal nerve. When the pain radiates down the back of the leg to the calf or foot, it would in lay terms be described as sciatica. This type of pain is often deep and steady, and can usually be reproduced with certain activities and positions, such as sitting or walking.

- See [What You Need to Know About Sciatica](#)



© Veritas Health, LLC

Watch: [Sciatica Animated Video](#)

The pain usually follows the involved dermatome in the leg - the area of distribution of the leg covered by the specific nerve. When a nerve at the L4-5 or L5-S1 level is affected (bottom two levels), this dermatome is usually the [sciatic nerve](#), which runs down the back of each leg to the foot.

Radicular pain may also be accompanied by numbness and tingling, muscle weakness and loss of specific reflexes. When actual nerve dysfunction is noted (prior noted symptoms), this is termed "[radiculopathy](#)".

Area of Pain Distribution

Radicular pain radiates into the lower extremity (thigh, calf, and occasionally the foot) directly along the course of a specific spinal nerve root. The most common symptom of radicular pain is sciatica (pain that radiates along the sciatic nerve - down the back of the thigh and calf into the foot). Sciatica is one of the most common forms of pain caused by compression of a spinal nerve in the low back. It often will be caused by compression of the lower spinal nerve roots (L5 and S1).

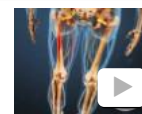With this condition, the [leg pain](#) is typically much worse than the low back pain, and the specific areas of the leg and/or foot that are affected depends on which nerve in the low back is affected. Compression of higher lumbar nerve roots such as L2, L3 and L4 can cause radicular pain into the front of the thigh and the shin.

Article continues below

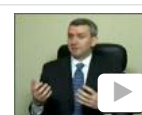Diagnosis of Lumbar Radiculopathy

A radiculopathy is caused by compression, inflammation and/or injury to a spinal nerve root in the low back. Causes of this type of pain, in the order of prevalence, include:

- **Herniated disc with nerve compression** - by far the most common cause of radiculopathy
- **Foraminal stenosis** (narrowing of the hole through which the spinal nerve exits due to bone spurs or arthritis) - more common in elderly adults
- **Diabetes**



[Sciatic Nerve Anatomy Video](#)



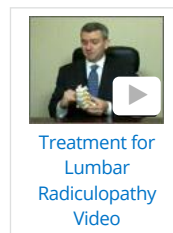
[Lumbar Radiculopathy Video](#)

- **Nerve root injuries**
- **Scar tissue from previous spinal surgery** that is affecting the nerve root

Sciatica, the term commonly used to describe radicular pain along the sciatic nerve, describes where the pain is felt but *is not an actual diagnosis*. The clinical diagnosis is usually arrived at through a combination of the patient's history (including a description of the pain) and a physical exam. Imaging studies (MRI, CT-myelogram) are used to confirm the diagnosis and will typically show the impingement on the nerve root.

Treatment of Lumbar Radiculopathy

It is usually recommended that a course of **nonsurgical treatment (such as physical therapy, medications, and selective spinal injections, among others)** should be conducted for six to eight weeks. If nonsurgical treatment does not alleviate the pain, decompressive surgery, such as laminectomy and/or [discectomy/microdiscectomy](#), may be recommended. This type of surgery typically provides relief of radicular pain/leg pain for 85% to 90% of patients. For patients with severe leg pain or other serious symptoms such as progressive muscle weakness, this type of surgery may be recommended prior to six weeks of non-surgical treatment. Back surgery for relief of radicular pain (leg pain) is much more reliable than the same surgery for relief of low back pain.



The decision to proceed with surgery is based on severity of leg pain and/or the presence of significant muscle weakness. It is important to note that if definitive nerve compression cannot be documented on an MRI or CT-myelogram, then back surgery is ill advised and unlikely to be successful.

✉ Get the latest news about back pain and other health and wellness topics direct to your inbox.

It's Free!

SUBSCRIBE

Health Information (Sponsored)

➤ [Artificial Disc Replacement and Fusion Surgery](#)

➤ [Combat Back Pain From Sitting All Day](#)

➤ [Chronic, Acute, and Complex Spine Conditions](#)

➤ [Best Mattress For Easing Back Pain](#)

➤ [Sacroiliac Joint Disor](#)

➤ [A comprehensive and minimally invasive spine surgery solution](#)

➤ [Scoliosis and Complex Revision Surgery](#)

➤ [Relief from Spinal Stenosis](#)

➤ [Considering Epidural Steroid Injections](#)

➤ [Cervical Spine Treatn Options](#)