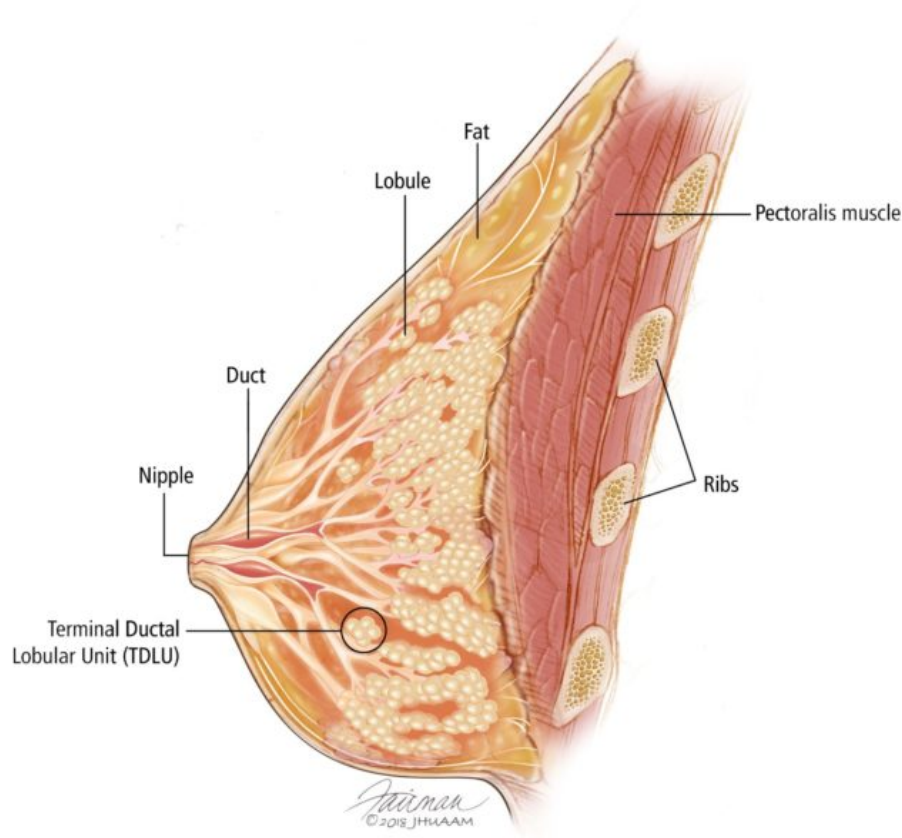


Overview of the Breast

BREAST CANCER HOME > BREAST BASICS > OVERVIEW OF THE BREAST

Learn about the normal anatomy of the breast.



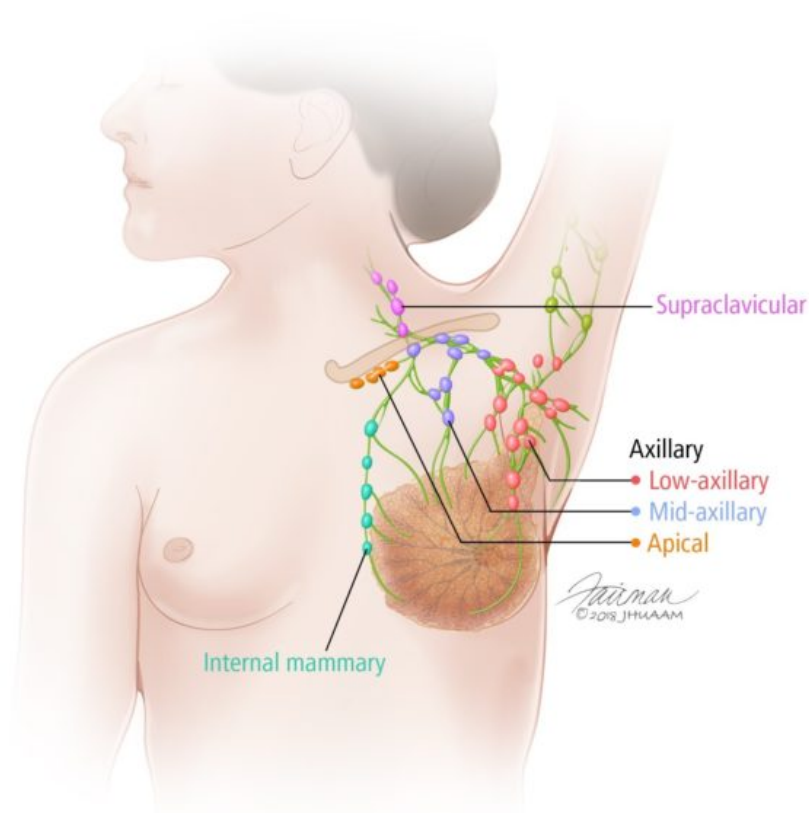
Anatomy & Physiology of the Breast

The breast is an organ whose structure reflects its special function: the production of milk for lactation (breast feeding). The epithelial component of the tissue consists of lobules, where milk is made, which connect to ducts that lead out to the nipple. Most cancers of the breast arise from the cells which form the lobules and terminal ducts. These lobules and ducts are spread throughout the background fibrous tissue and adipose tissue (fat) that make up the majority of the breast. The male breast structure is nearly identical to the female breast, except that the male breast tissue lacks the specialized lobules, since there is no physiologic need for milk production by males.

Anatomically, the adult breast sits atop the pectoralis muscle (the "pec" chest muscle), which is atop the ribcage. The breast tissue extends horizontally (side-to-side) from the edge of the sternum (the firm flat bone in the middle of the chest) out to the midaxillary line (the center of the axilla, or underarm). A tail of breast tissue called the "axillary tail of Spence" extend into the underarm area. This is important because a breast cancer can develop in this axillary tail, even though it might not seem to be located within the actual breast.

The breast tissue is encircled by a thin layer of connective tissue called fascia. The deep layer of this fascia sits immediately atop the pectoralis muscle, and the superficial layer sits just under the skin. The skin covering the breast is similar to skin elsewhere on the body and has similar sweat glands, hair follicles, and other features. A clinician will examine the skin in addition to the breast tissue itself when performing a breast exam.

Wondering About Symptoms of Breast Cancer?

[Learn More Now](#)

Blood Supply & Lymph Nodes

The blood supply from the breast comes primarily from the internal mammary artery, which runs underneath the main breast tissue. The blood supply provides nutrients, such as oxygen, to the breast tissue. The lymphatic vessels of the breast flow in the opposite direction of the blood supply and drain into lymph nodes. It is through these lymphatic vessels that breast cancers metastasize or spread to lymph nodes. Most lymphatic vessels flow to the axillary (underarm) lymph nodes, while a smaller number of lymphatic vessels flow to internal mammary lymph nodes located deep to the breast. Knowledge of this

lymphatic drainage is important, because when a breast cancer metastasizes, it usually involves the first lymph node in the chain of lymph nodes. This is called the "sentinel lymph node," and a surgeon may remove this lymph node to check for metastases in a patient with breast cancer.

Many additional changes are seen in the breast tissue during pregnancy and lactation due to the changes in hormones during those times.

© 2018 Johns Hopkins University



Breast Basics

Explain My Results

My Options

The Pathologist's Role

Our Team